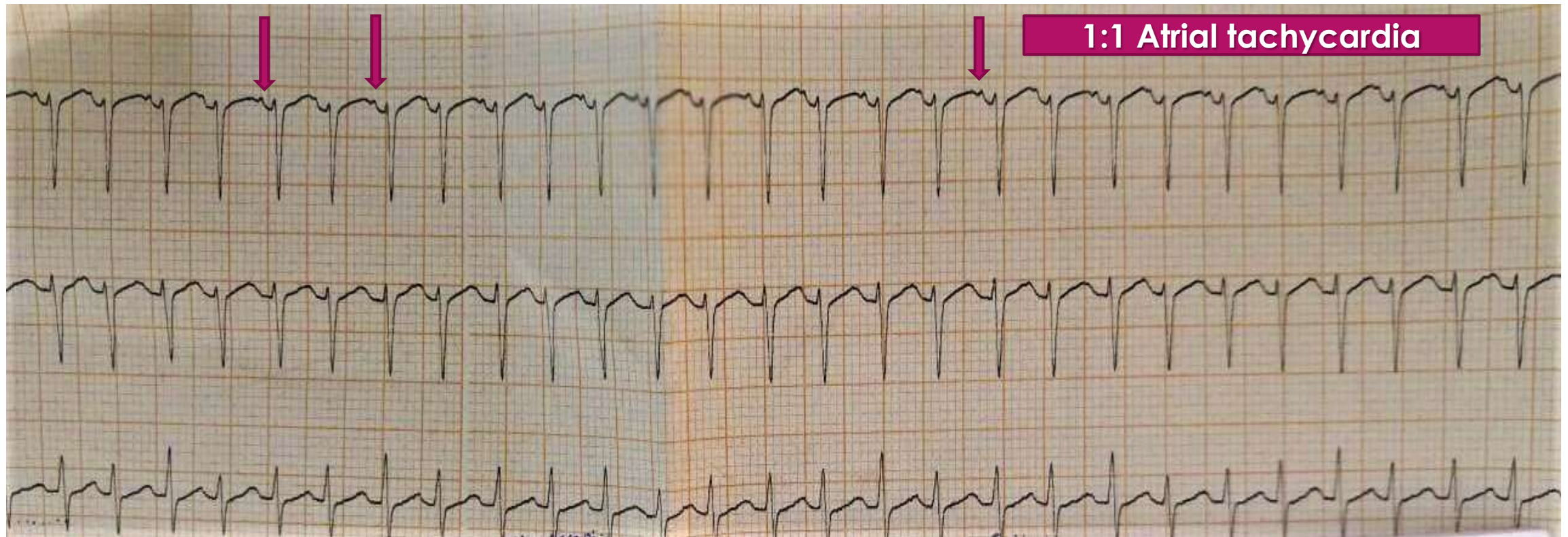


Atrial Arrhythmia in a 5-chambered heart!

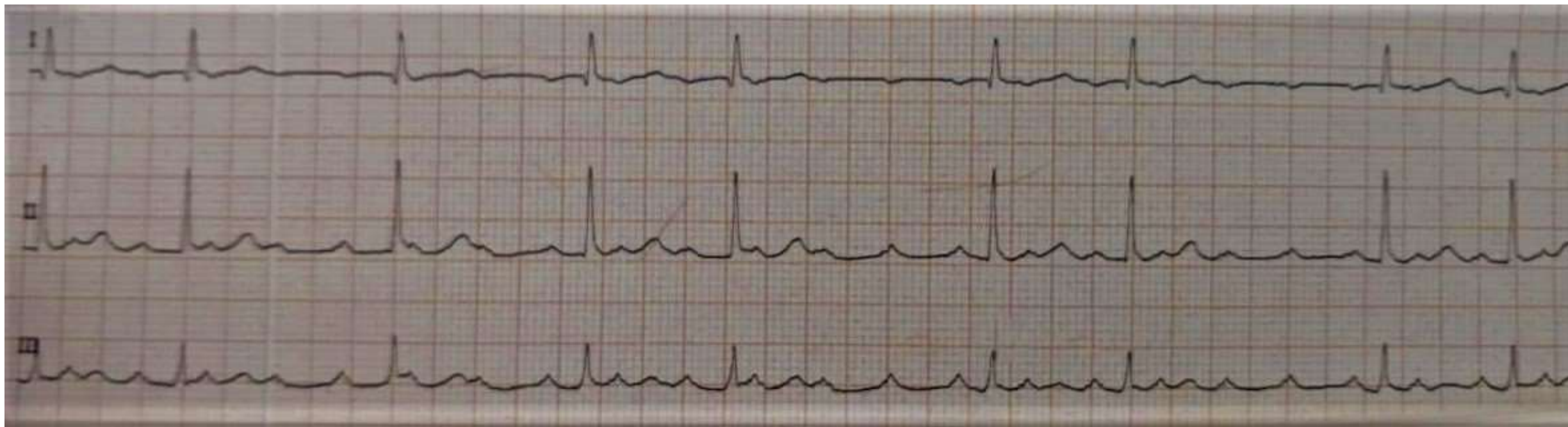
- ▶ 33 year old male
- ▶ Previously asymptomatic cardiac status presented with history of recent onset recurrent palpitations and giddiness

Dr Ranjeet Palkar DNB (Card), Dr S Mukhedkar DM, Dr A Bhagwat DM

Event ECG: Narrow QRS regular tachycardia

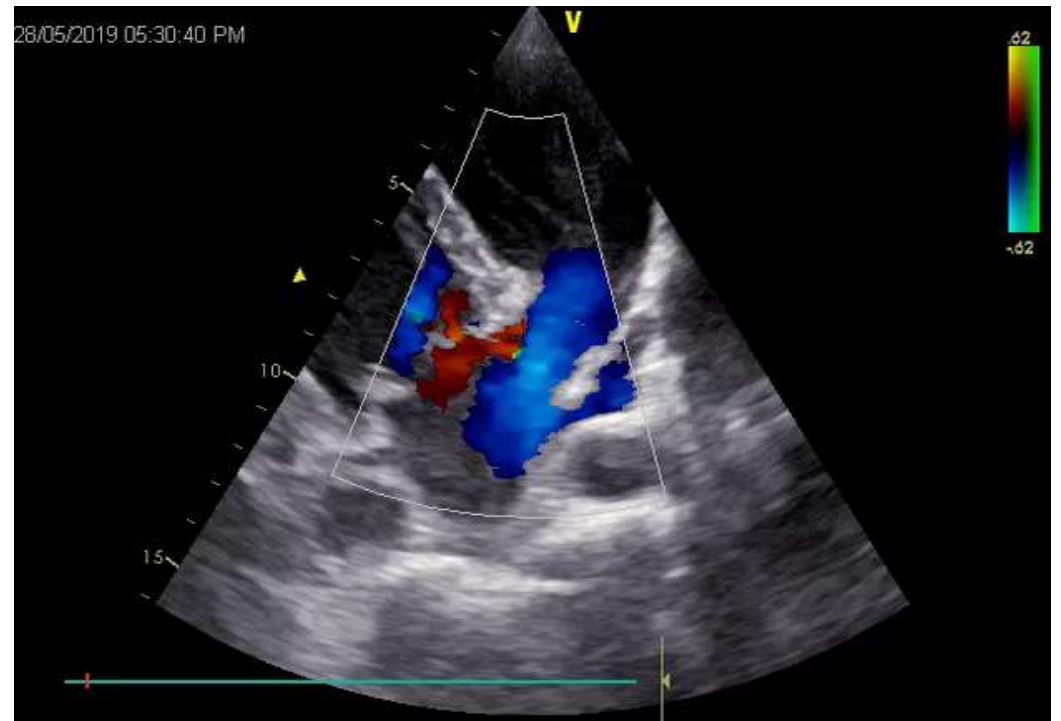
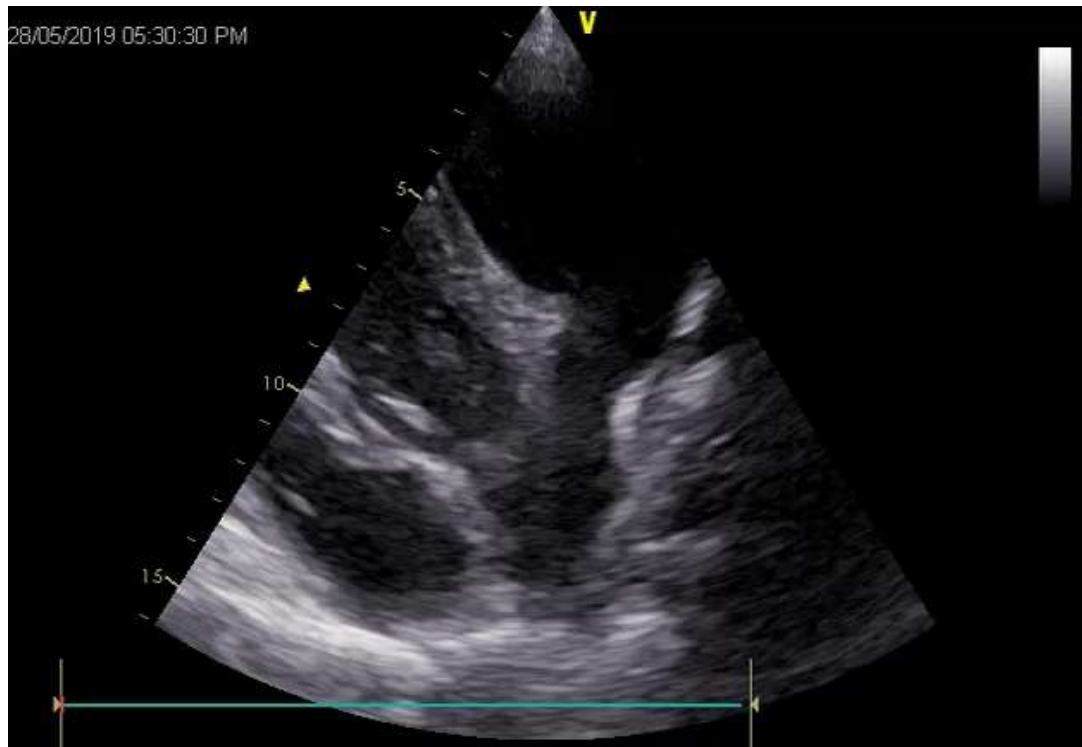


Post IV Amiodarone: Definite Atrial tachycardia



ROLE OF ECHOCARDIOGRAPHY

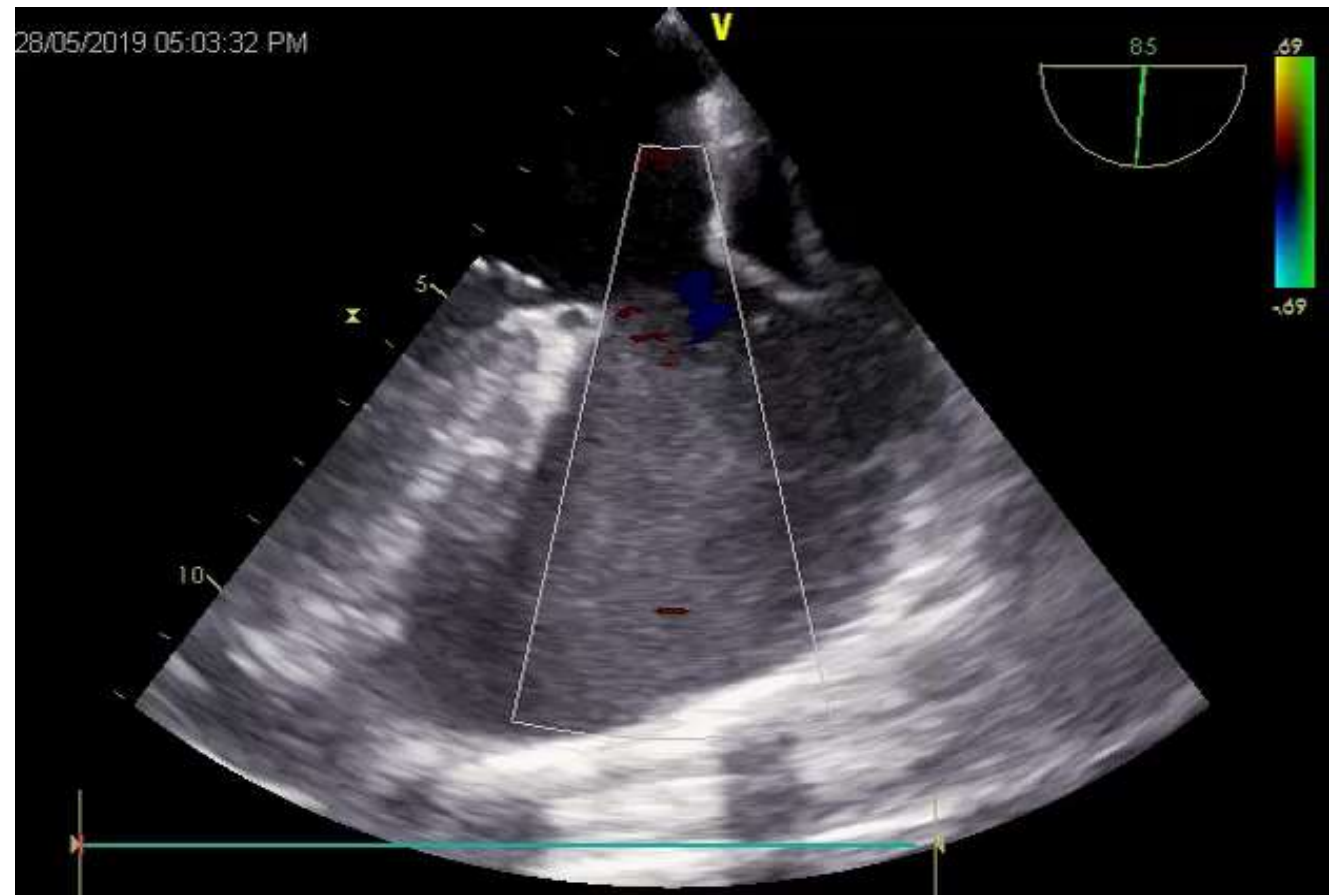TTE: Exchange of blood
between LA-LAA



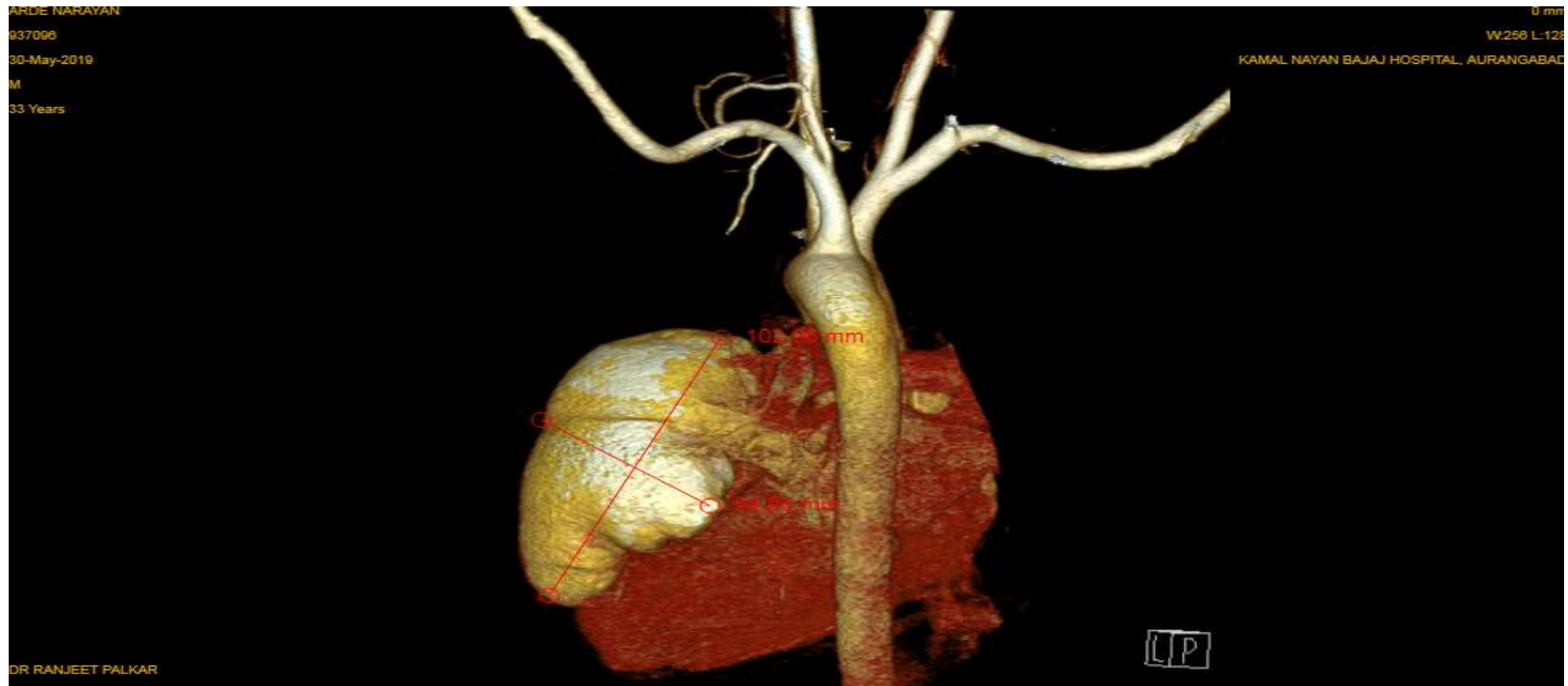Trans- Esophageal echocardiogram

TEE image
showing
spontaneous
echo contrast in
A giant LA
Appendage
aneurysm

TEE: Visualizes surrounding structures
and resolves DD



CT image showing Giant LA appendage aneurysm measuring 10.5 x 7.3 x 5.4 cm



Left Atrial Appendage Aneurysm: The 5th Chamber!

- ▶ LAAA, a congenital disorder. Overall, 89 case reports and 6 case series of LAAA were identified.
- ▶ May manifest as palpitations, shortness of breath, and cerebrovascular events. Often, incidentally diagnosed.
- ▶ Atrial fibrillation and atrial flutter are the most common associated arrhythmias.
- ▶ Surgical treatment is often recommended even in asymptomatic patients, as it can prevent the potential thromboembolic complications and treat associated atrial arrhythmias.