# ECG in Unstable Angina

Anoop K. Gupta
MD, DM, DNB, FACC, FESC, FSCAI
AHMEDABAD

ISECON 2019, Kolkata 24-26 May, 2019

# Unstable angina

- Left main or severe triple vessel disease
- Critical proximal LAD lesion
- Other vessels

# ECG 1

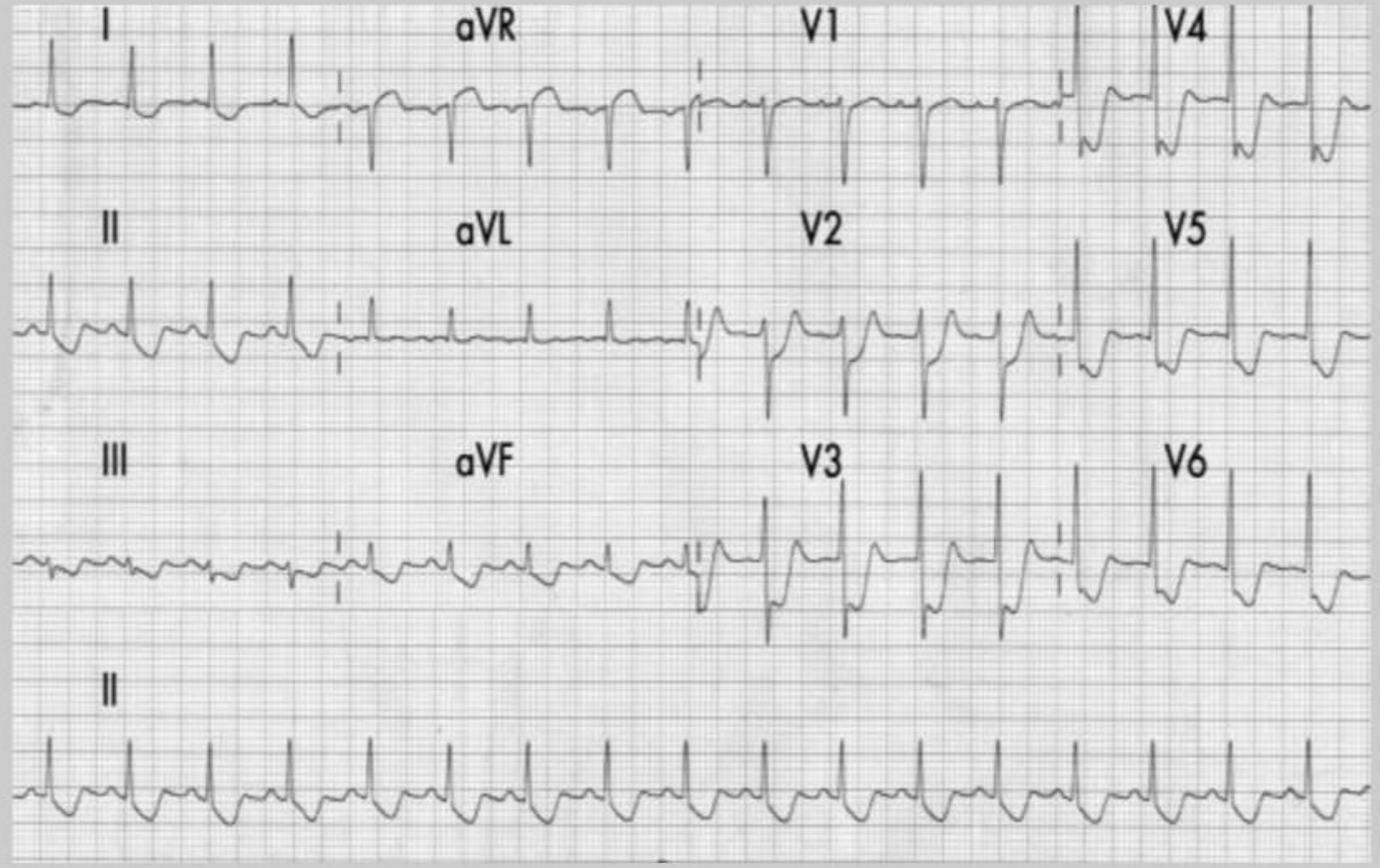

# Left main and Three vessel disease

- ST elevation in V1 and aVR + ST segment depression in eight or more leads, the chance of LM disease or TVD is 71%[1]

- More frequent in V3-V5, greatest in V4 (67% patients)[2]

- 25% patients with significant LM disease have normal ECG during pain free period


1. Wellens, HJJ et al. Circulation 1988; 78: 1682-86.
2. Smeets, JLR et al. Circulation 1989; 80: 154-162.

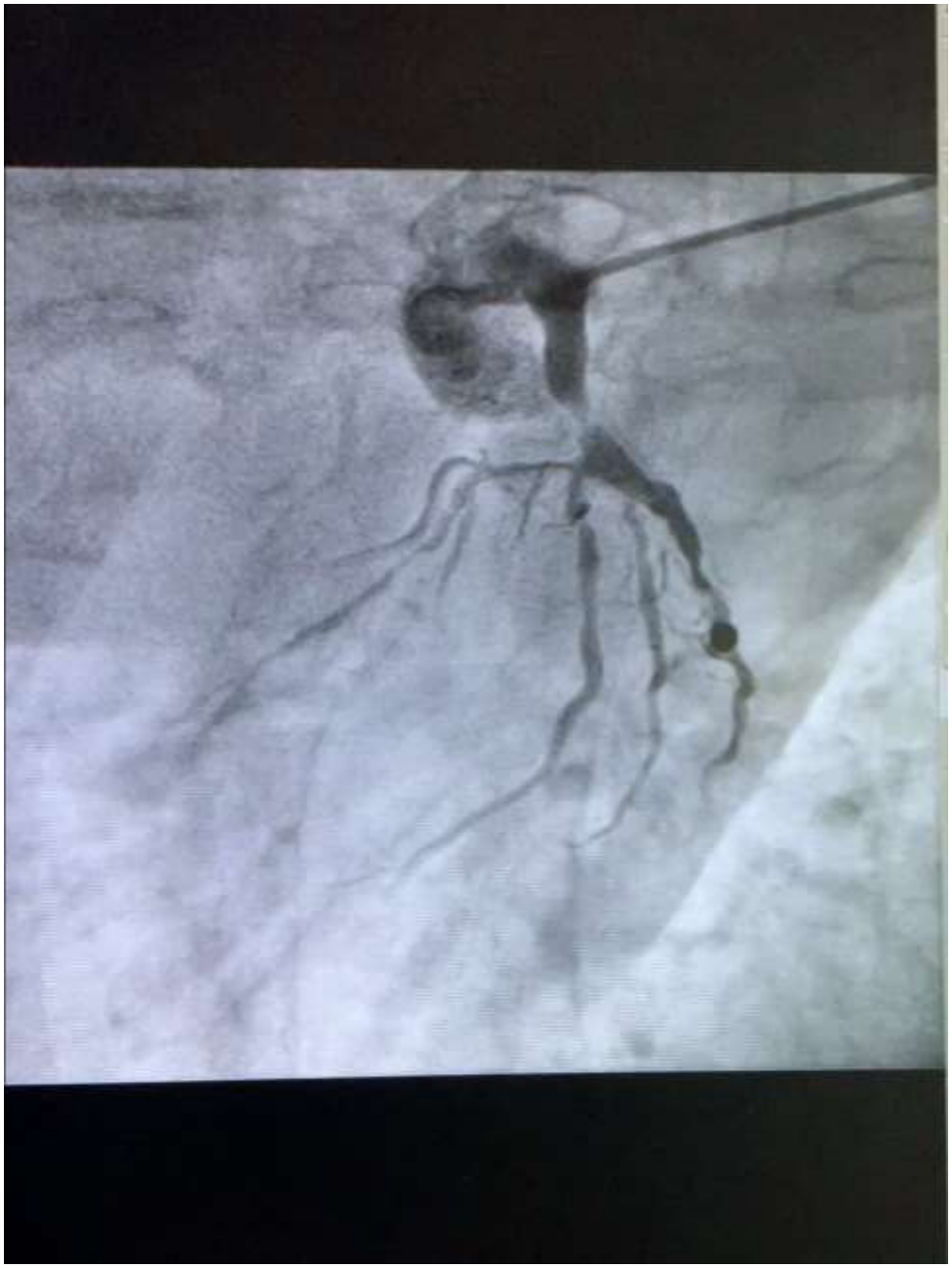

# ECG 2

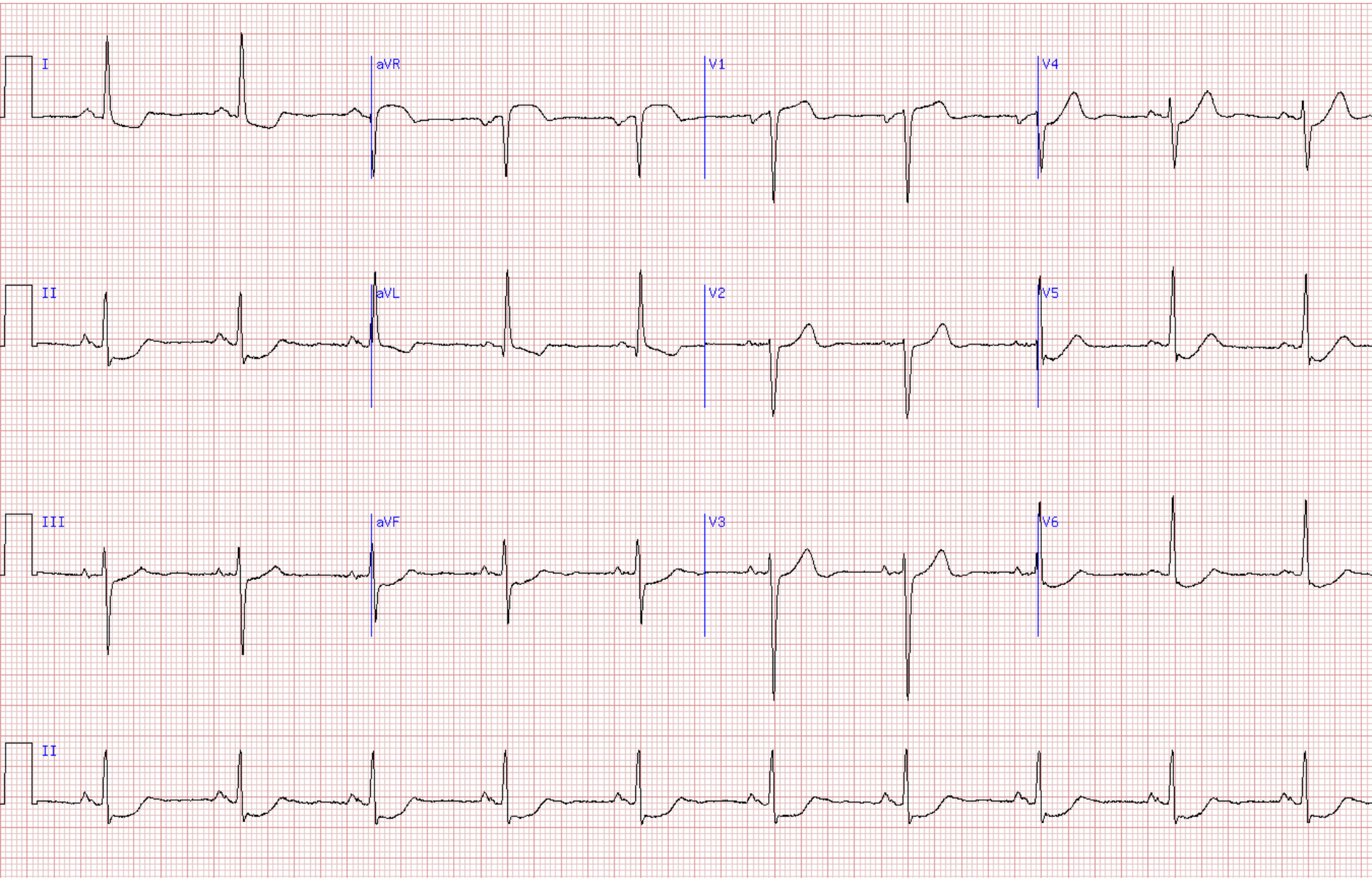

# Multi-vessel disease

- The ECG shows left ventricular hypertrophy (LVH) by voltage plus left atrial abnormality (LAA). The QRS axis is without frank left axis deviation or evidence for left anterior fascicular block.

- Although LVH alone may be associated with ST-T abnormalities (sometimes referred to as a "strain pattern"), like those in lead aVL, the prominent horizontal or downsloping ST depressions in other leads (I, II, aVF, V5, V6) here are strongly suggestive of ischemia superimposed on LVH.

- Importantly, the concomitant ST elevations in aVR.exceeding those in lead V1 strongly suggest three vessel disease and sometimes left main stenosis.

# Mechanism of ST elevation in aVR

- Lead aVR is electrically opposite to the left-sided leads I, II, aVL and V4-6; therefore ST depression in these leads will produce reciprocal ST elevation in aVR.

- Lead aVR also directly records electrical activity from the right upper portion of the heart, including the right ventricular outflow tract and the basal portion of the interventricular septum. Infarction in this area could theoretically produce ST elevation in aVR.

# Predictive Value of ST elevation in aVR

- STE in aVR ≥ 1mm indicates proximal LAD / LMCA occlusion or severe 3VD
- STE in aVR ≥ 1mm predicts the need for CABG
- STE in aVR ≥ V1 differentiates LMCA from proximal LAD occlusion
- Absence of ST elevation in aVR almost entirely excludes a significant LMCA lesion

# LMCA mimics

- Widespread ST depression (with reciprocal STE in aVR) is a common finding in patients with supraventricular tachycardias such as AVNRT or atrial flutter. The significance of this finding in individual patients is unclear, and may be due to:

  - Rate-related ischaemia (O2 demand > supply)
  - Unmasking of underlying coronary artery disease (i.e. tachycardia as a “stress test”)
  - A pure electrical phenomenon (e.g. the young patient with SVT who is relatively asymptomatic and has normal coronary arteries)

# Paroxysmal Supraventricular tachycardia

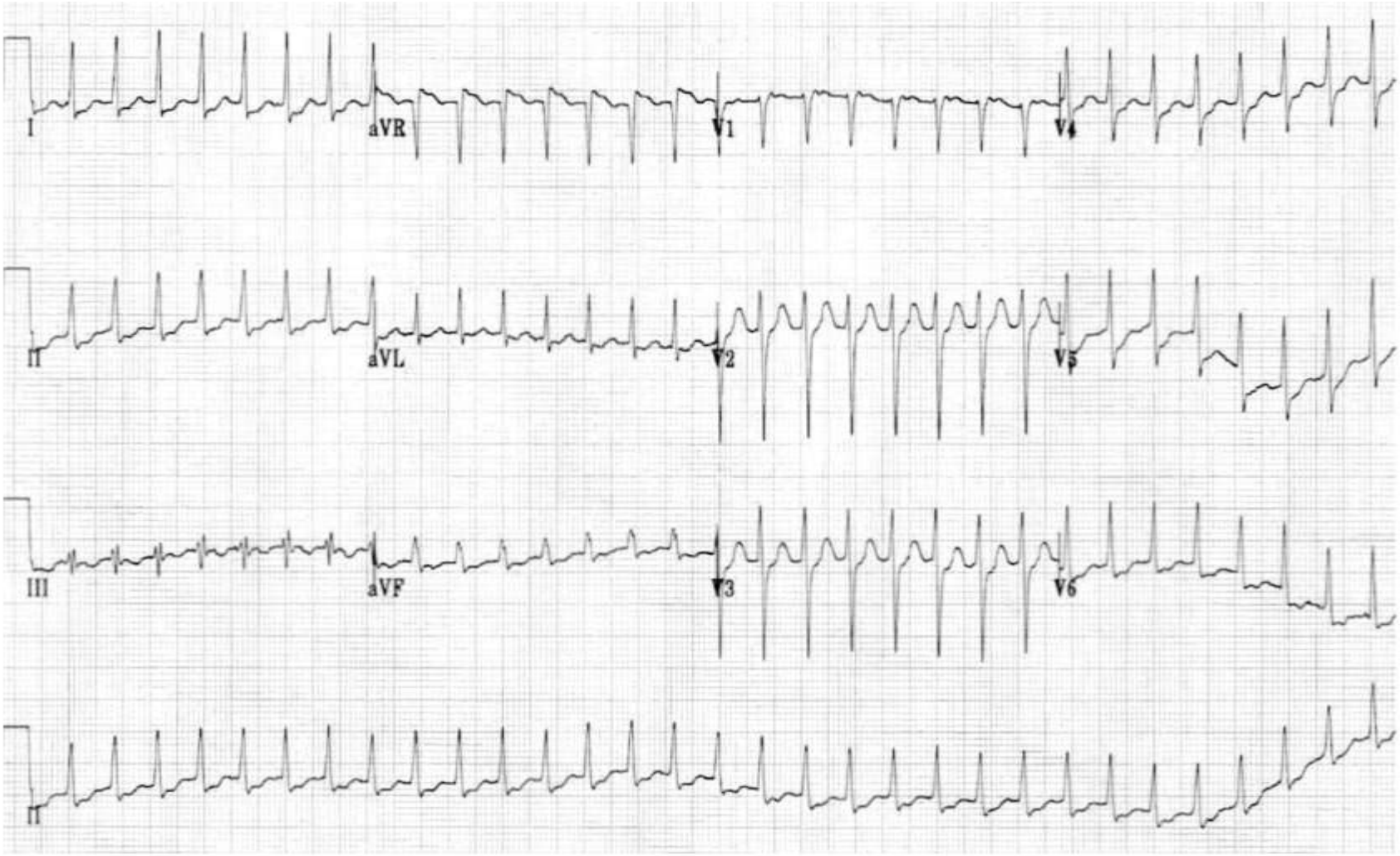

# Atrial Flutter with 2: 1 block

# ECG 3

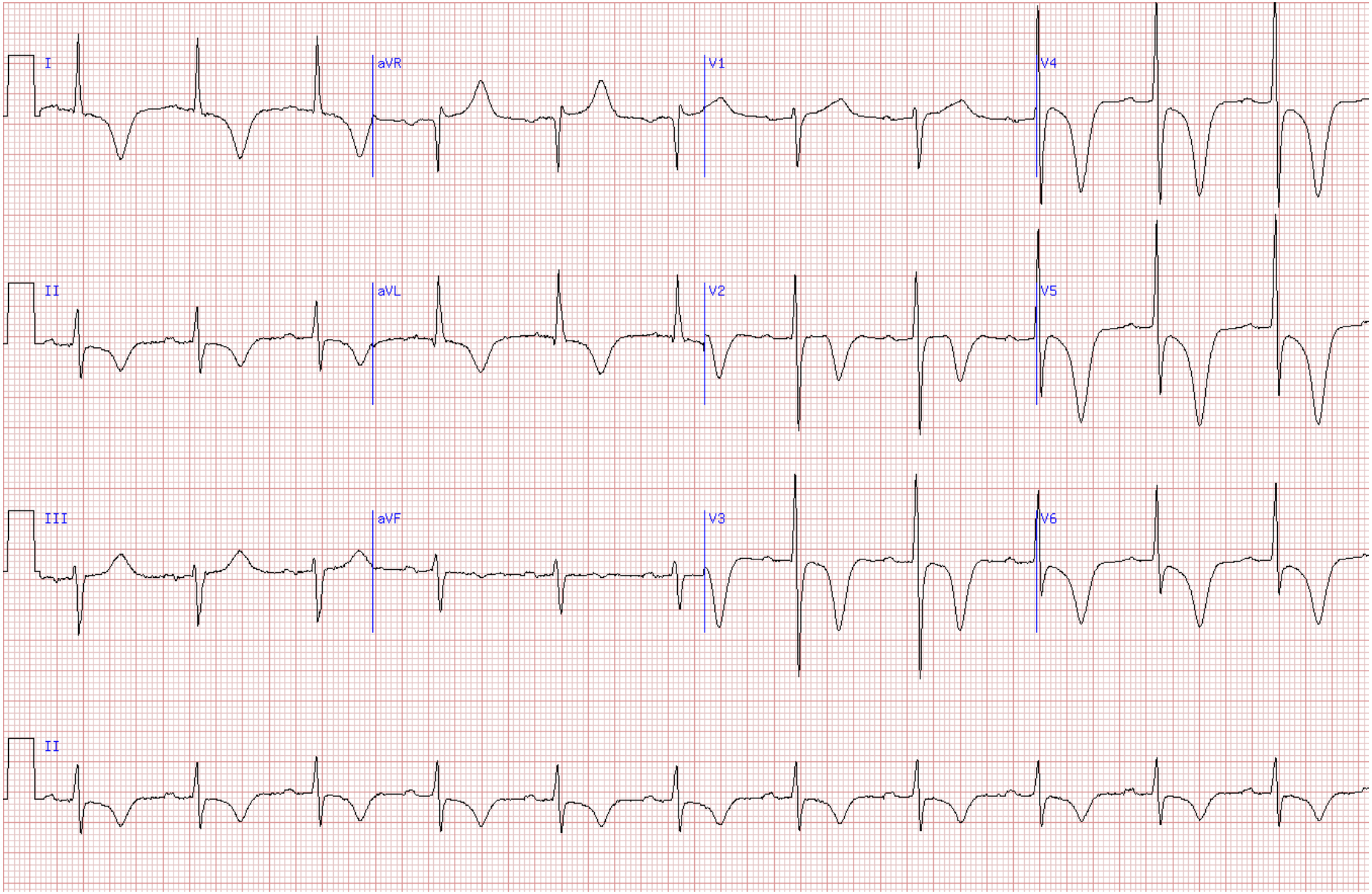

# Critical proximal LAD Stenosis

- During Pain free period: progressive, deep , symmetrical T wave inversion; the angle between the ST segment and down slope of T wave is 60-90 degrees[1]
- During angina: positive T wave changes
- Commonest in lead V2-V3
- 60% at the time of admission[2]


1. Wellens, HJJ et al. Am Heart J 1982; 103: 730-35
2. deZwaan et al: Am Heart J 1989;117: 657-60.

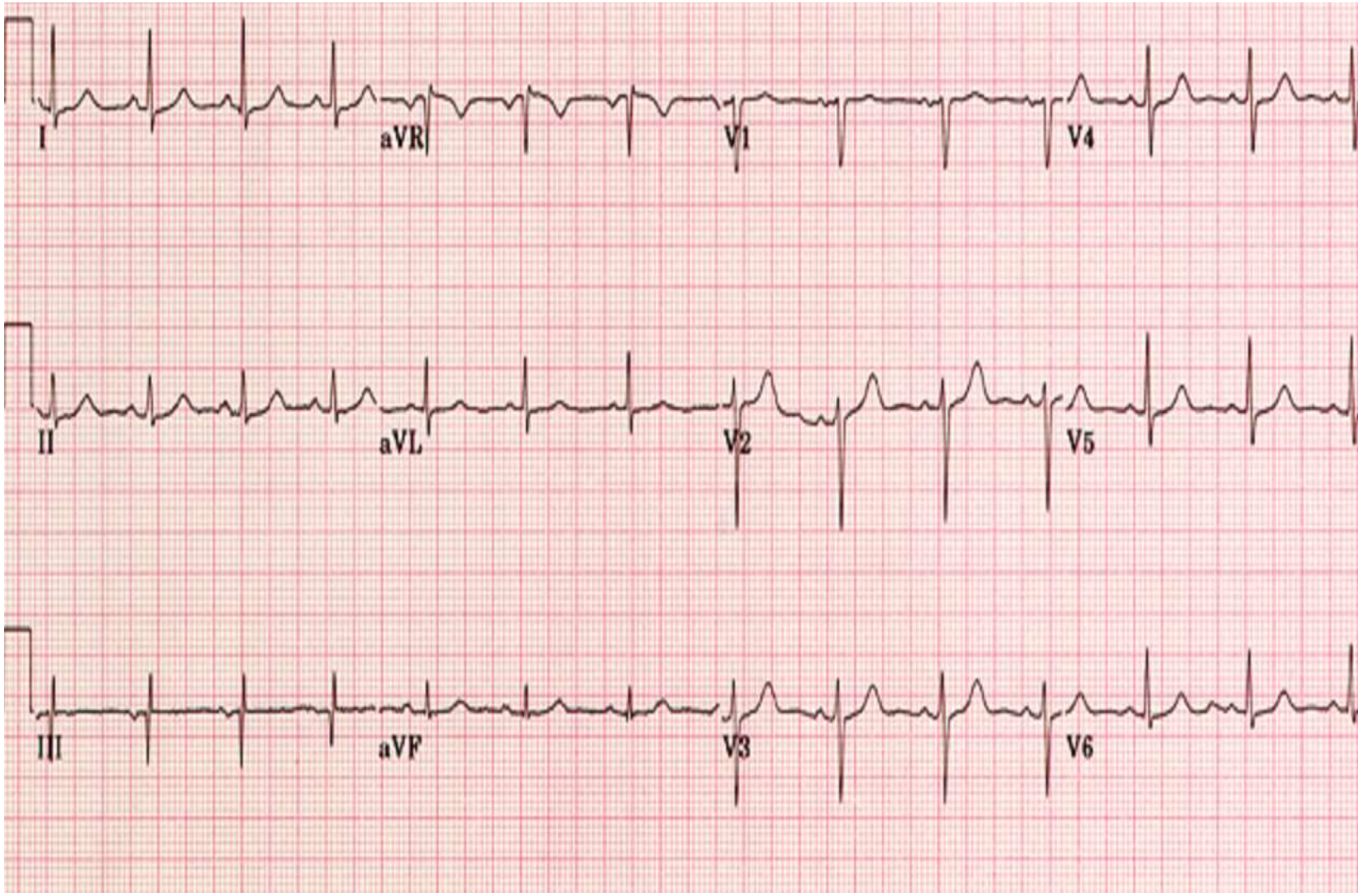
I
aVR
V1
V4
II
aVL
V2
V5
III
aVF
V3
V6

# Differential diagnosis

1. CNS disease—(intracranial hemorrhage, head injury, tumor)

2. Apical hypertrophic cardiomyopathy (usually most marked in the mid-lateral precordial leads

3. Intermittent right ventricular pacing or intermittent LBBB ("memory T waves”)

4. Takotsubo (stress) cardiomyopathy (left ventricular apical "ballooning" pattern on angiogram)


ANGUR BALA JAIN / F 47 / PTCA
D E-6591 \ F
DOB
Acc. #A20190501110746 4
5/1/2019
St.ID R20190501110746 4
722028-716 100179644 50036703 01 0 0041
SE. #2
XA
Left Coronary 15 fps
Im. #2
11:29:57 AM
Zoom: 183%
PS:
VOI:
WC: 127.50
WW: 255.00
LAO: 2.30000000000000
CRAN: -32.36


ANGUR BALA JAIN / F 47 / PTCA
D E-6591 \ F
DOB
Acc. #A201905011107464
5/1/2019
St.ID R201905011107464
722028-716 100179644 50036703 01 0 004
SE. #2
XA
Left Coronary 15 fp
Im. #22
11:41:01 AM
Zoom: 183%
PS:
VOI:
WC: 127.50
WW: 255.00
LAO: -2.15

ECG 4

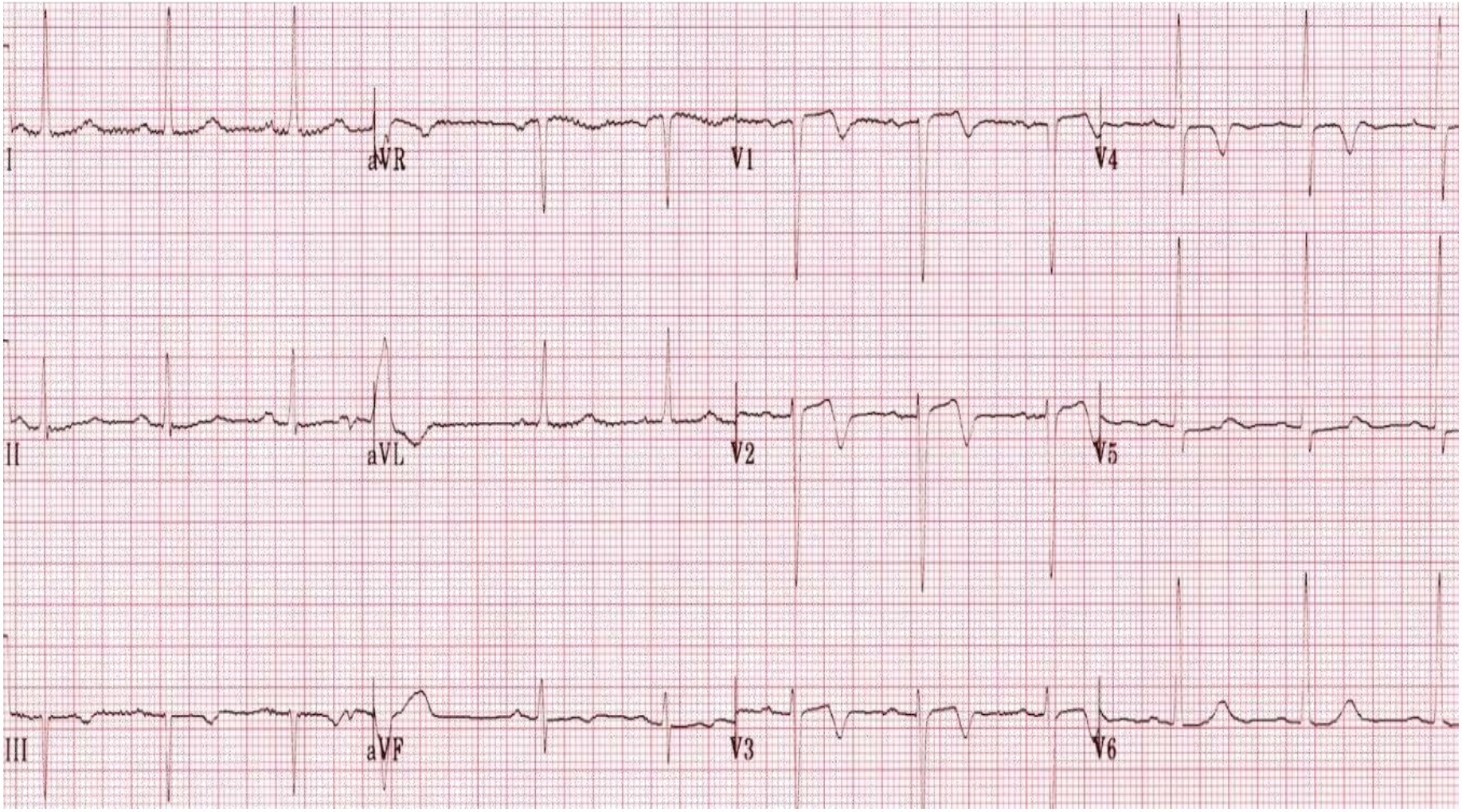

# Typical Angina pain

- The key findings are biphasic ST-T waves (ST elevations that are arched or bowed upward, followed by prominent, negative T waves) in anterior precordial leads V1-V4.

- These findings, especially in the context of anginal-type chest discomfort or other ischemic symptoms, are highly suggestive of a high-grade stenosis of the proximal left anterior descending (LAD) coronary artery.

- The “LAD-T wave pattern” is also known as Wellens’ syndrome. Patients with this ECG finding are at very high risk of subsequent major, near-term anterior myocardial infarction.

- Wellens and colleagues suggested a sub-classification of this pattern into Types A and B based on repolarization morphology, depending on whether there was ST elevation preceding the T waves, as seen here (A) or an isoelectric or depressed ST segment (B).

# ECG 5

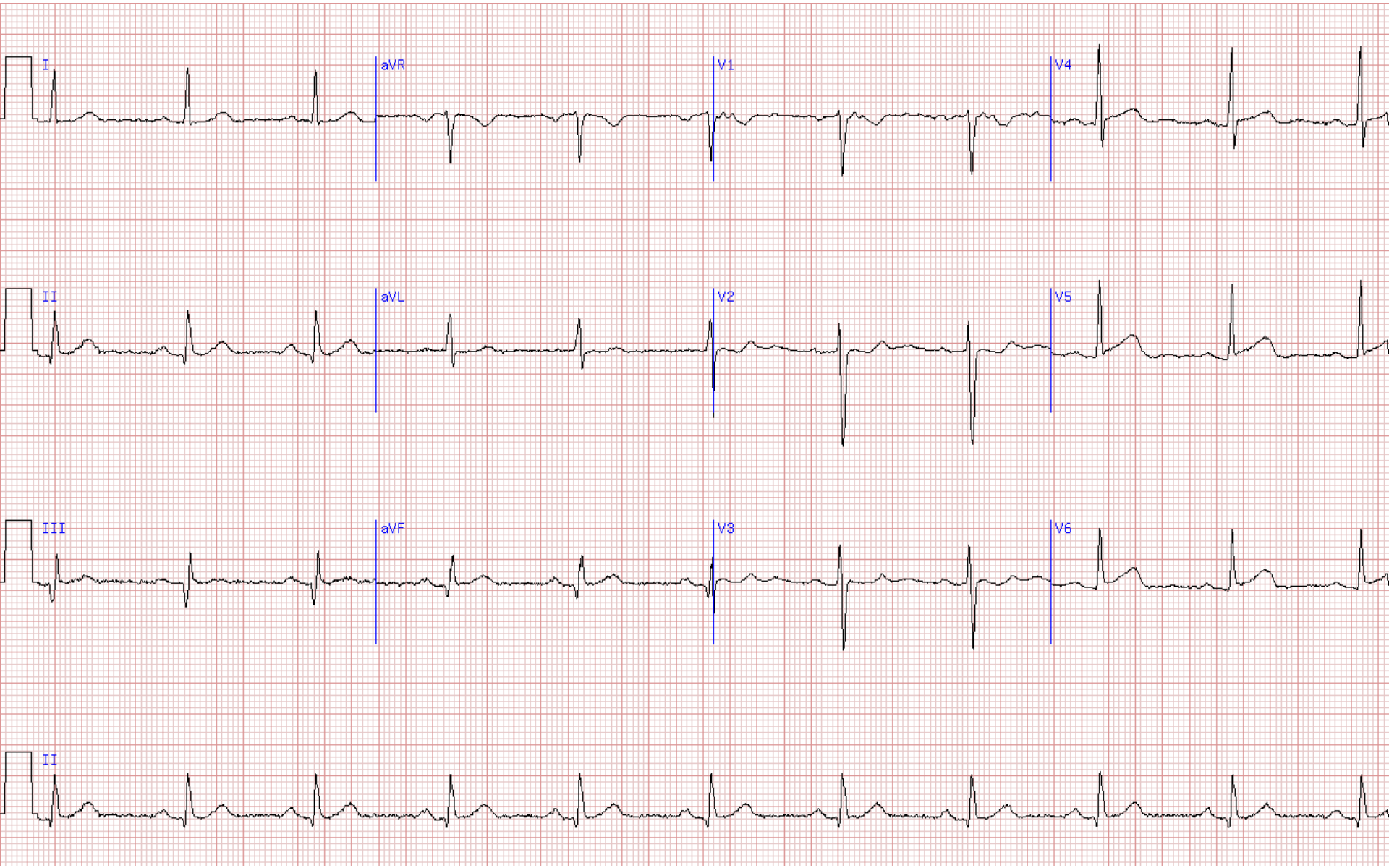

# Lateral wall trans-mural ischemia

- There are ST elevations in V4, V5 and V6 with subtle ST straightening and minimal ST depression consistent with and reciprocal change in leads V2 and V3 in this context.

- Differential diagnosis of ST elevations in this context also includes normal variant early repolarization. But this is not likely because the changes are in V5/V6 mainly, not the mid chest leads and there are likely reciprocal changes in V2 and V3 which excludes pericarditis as well.

- The patient had an occluded left circumflex artery at cardiac catheterization/coronary angiography.

# ECG 6

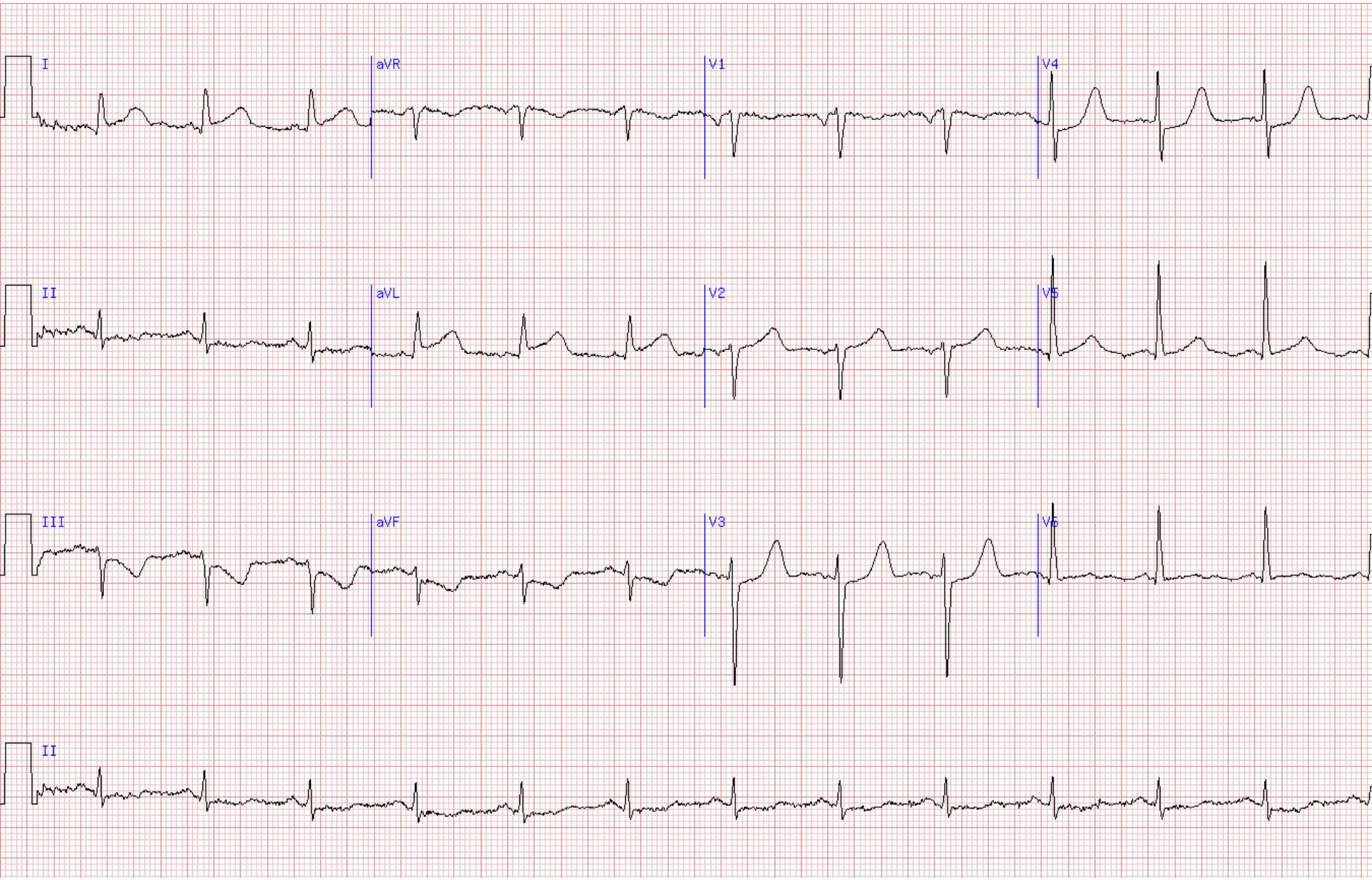

# Acute Lateral Wall Ischemia

- ST elevations in I and aVL with probable reciprocal ST depressions inferiorly consistent with acute lateral ischemia/MI.

- Remember that ST elevations like this are never reciprocal but indicate the primary region of ischemia, suggestive of diagonal or circumflex lesion.

# ECG 7

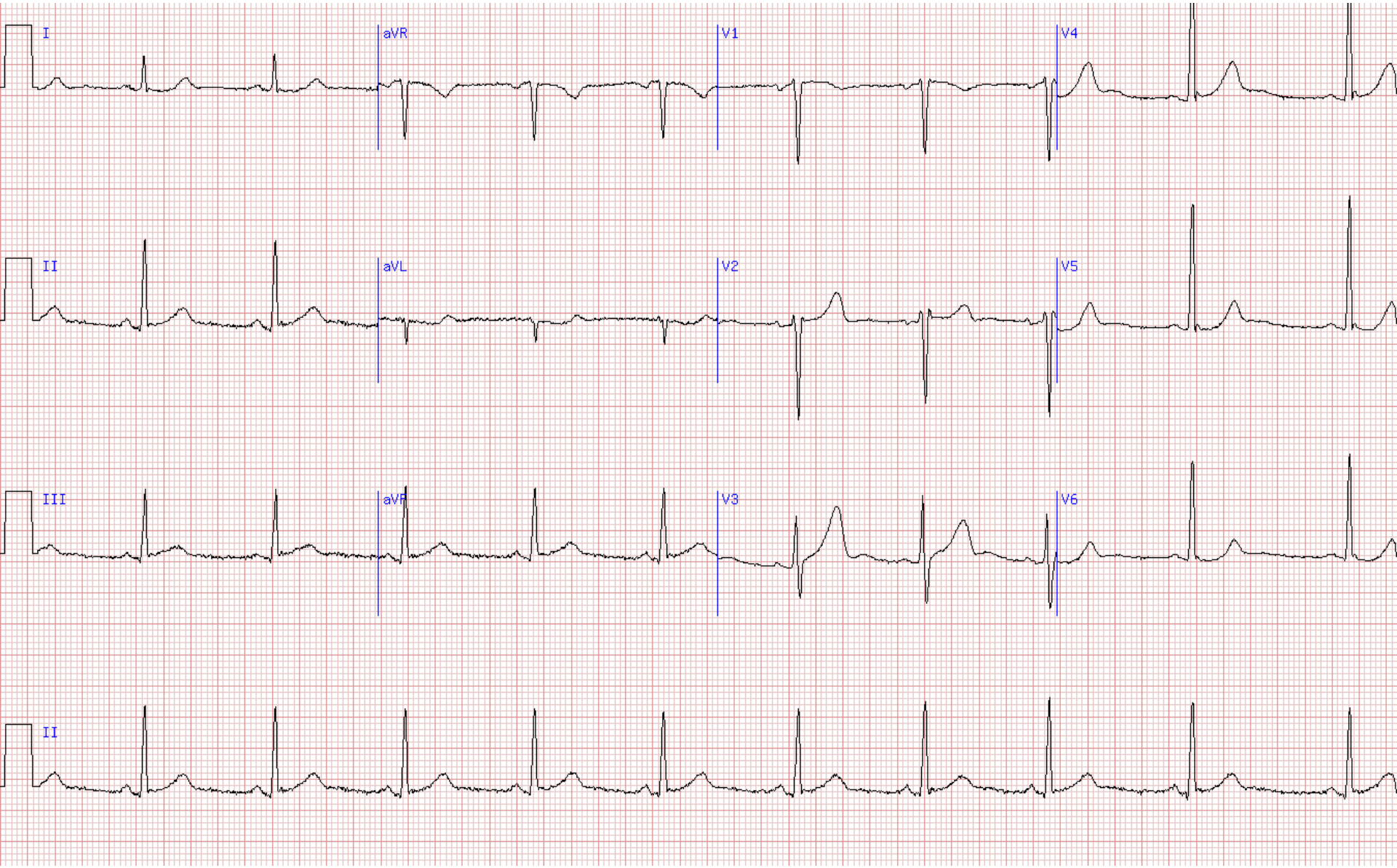

# Acute inferior transmural ischemia/MI.

- Very subtle ST elevations and ST straightening in inferior leads with reciprocal ST depressions in aVL.
- Such reciprocal changes are not seen with pericarditis or early repolarization variant.
- The patient had a high grade proximal right coronary artery lesion. He was treated with a percutaneous transluminal coronary intervention procedure and ruled in for MI.

# ECG 8

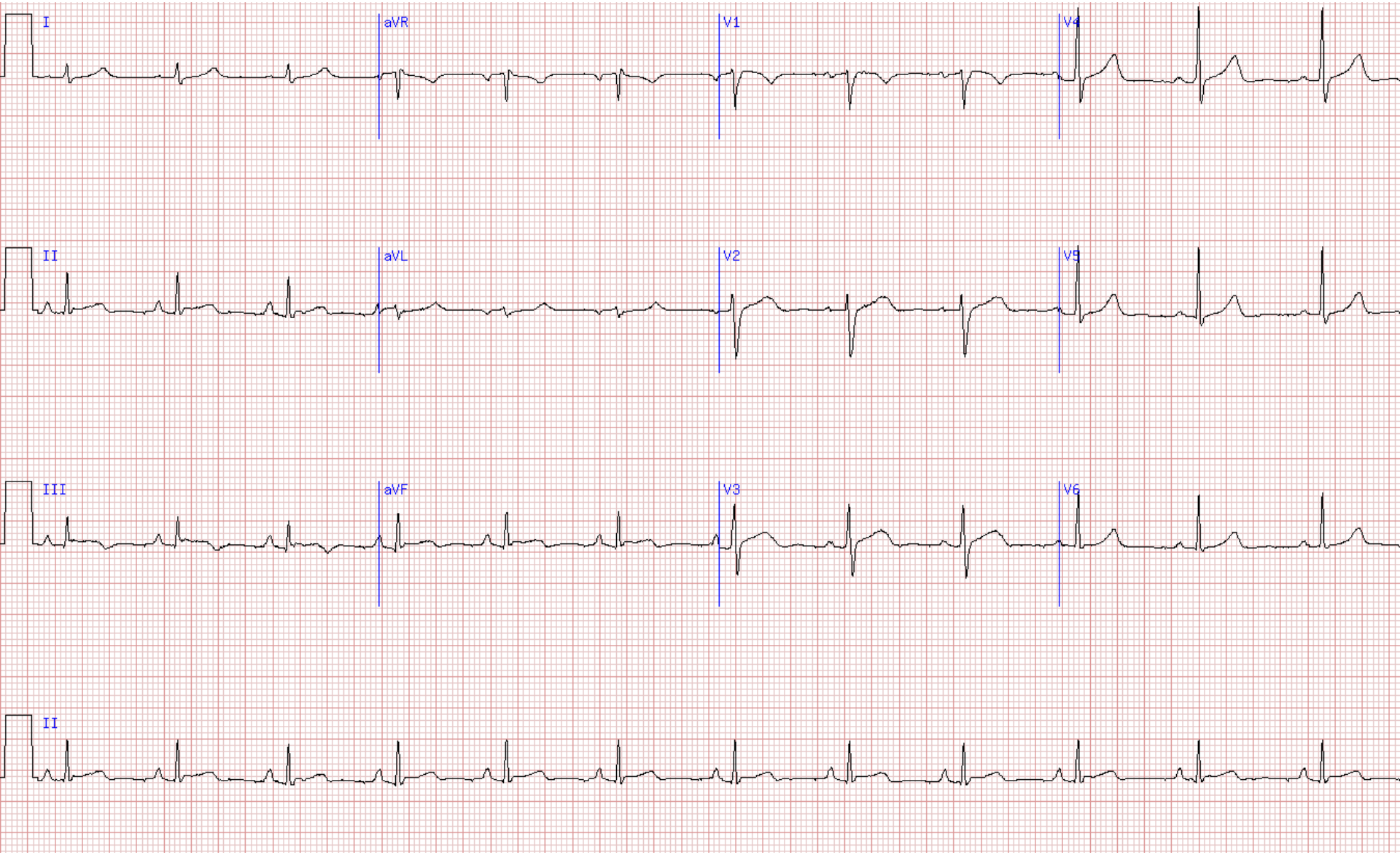

# NSTEMI: IWMI

- Note slight inferior ST elevation with T wave inversion.
- There is also minimal reciprocal ST depression in aVL.
- Relatively low limb lead voltage makes these findings more subtle.

# ECG 9

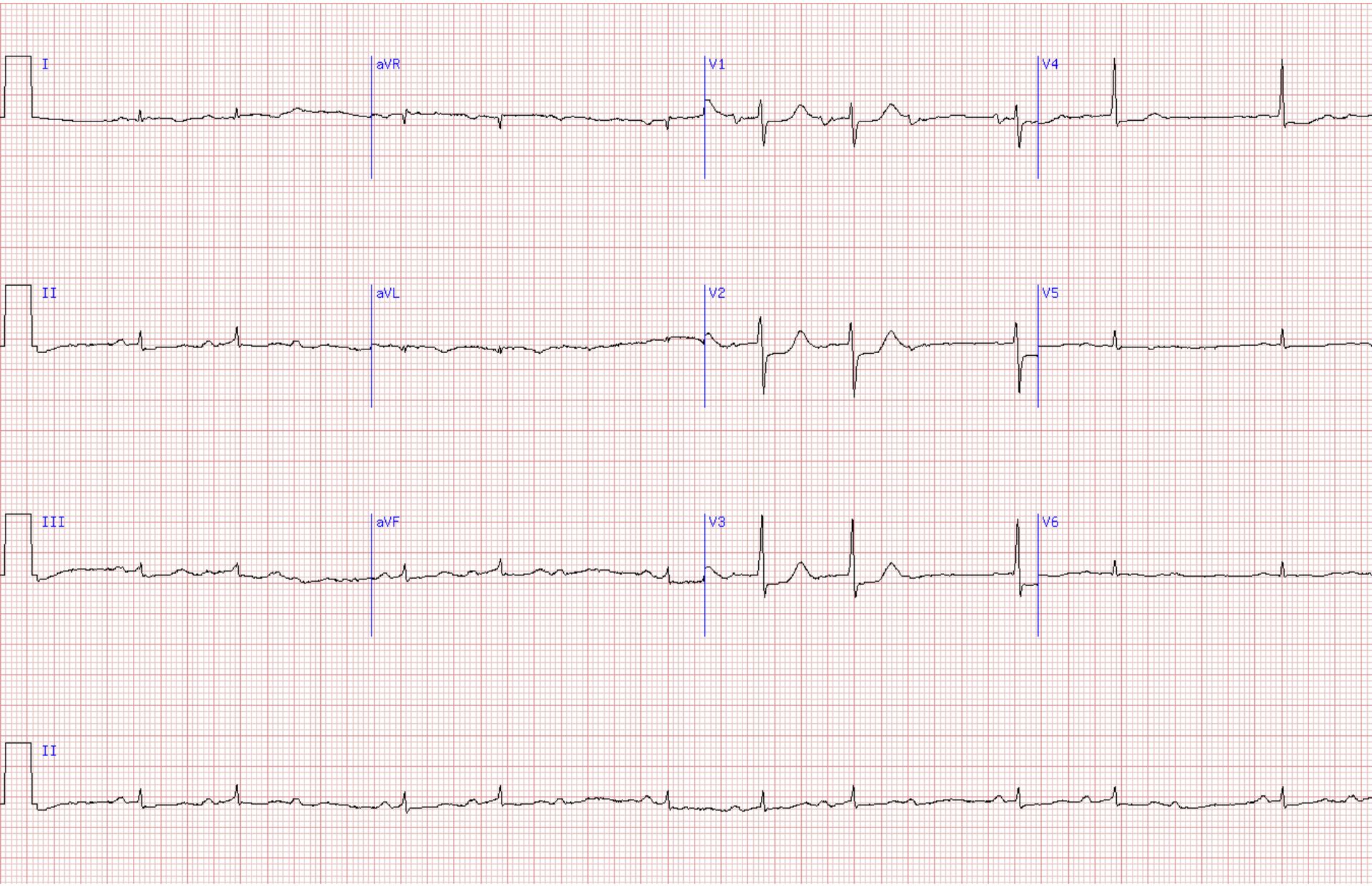

# Rhythm disturbance

- AV Wenckebach (3:2 and 4:3 AV ) conduction. This conduction problem is present in the context of an evolving postero-lateral myocardial infarction (MI).

- Very subtle ST elevations in I, relative to the TP baseline, in concert with "coved" T waves in I and aVL and V5, V6. ST depressions in V1-V2 are consistent with reciprocal changes (to the postero-lateral ST elevations).

- The prominent right precordial R waves are likely related to loss of QRS forces in the postero-lateral part of the heart.

- Note that sometimes reciprocal ST depressions are more prominent that primary ST elevations

Goldberger AL, Erickson R. Pacing Clin. Subtle ECG sign of acute infarction: prominent reciprocal ST depression with minimal primary ST elevation.
Pacing Clin Electrophysiol 1981; 4: 709-12.

# ECG 10

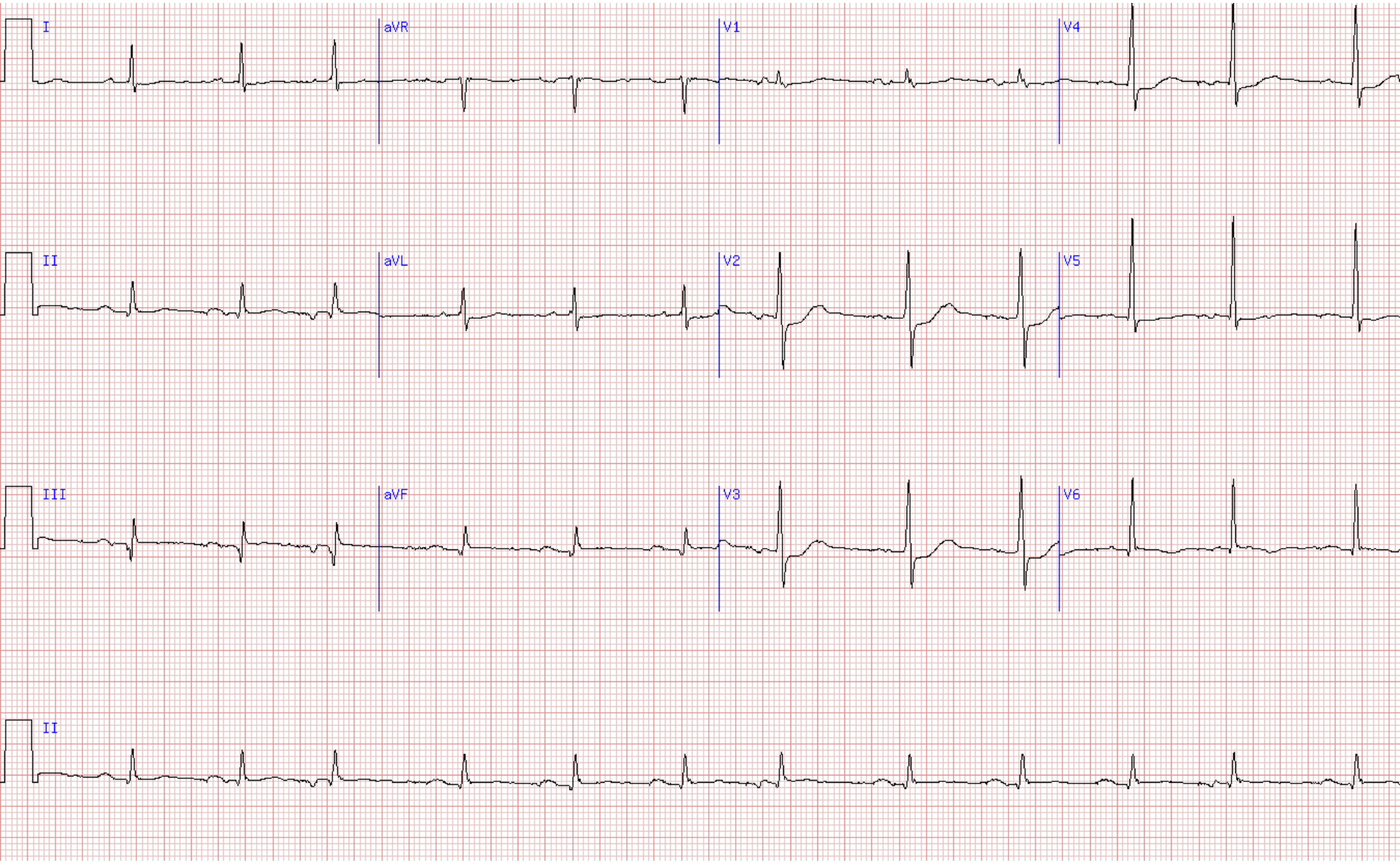

# Infero-posterior Lateral MI

- The relatively tall R waves in the right precordial leads are associated with low amplitude but wide Q waves inferiorly, consistent with prior inferior-posterior myocardial infarction (MI).

- There is slight ST elevation and T-wave inversion in V6, consistent with evolving lateral ischemia/myocardial infarction.

# Conclusions

- History, clinical profile, ECG should be correlated before making final diagnosis.
- Risk stratification
- Serial ECG should be obtained

**Thank you for your attention**