Respect the neglected Lead aVR

Prof. Dr Rabin Chakraborty

MD, MRCP, DNB, FRCP (London), FRCP (Glasgow), FRCP (Ireland), FACC (USA), FICP, FICC, FISE, FCSI, DM (Cardiology)

Senior Vice Chairman and Head

Cardiology Services

Medica Superspecialty Hospital, Kolkata

Normal ECG

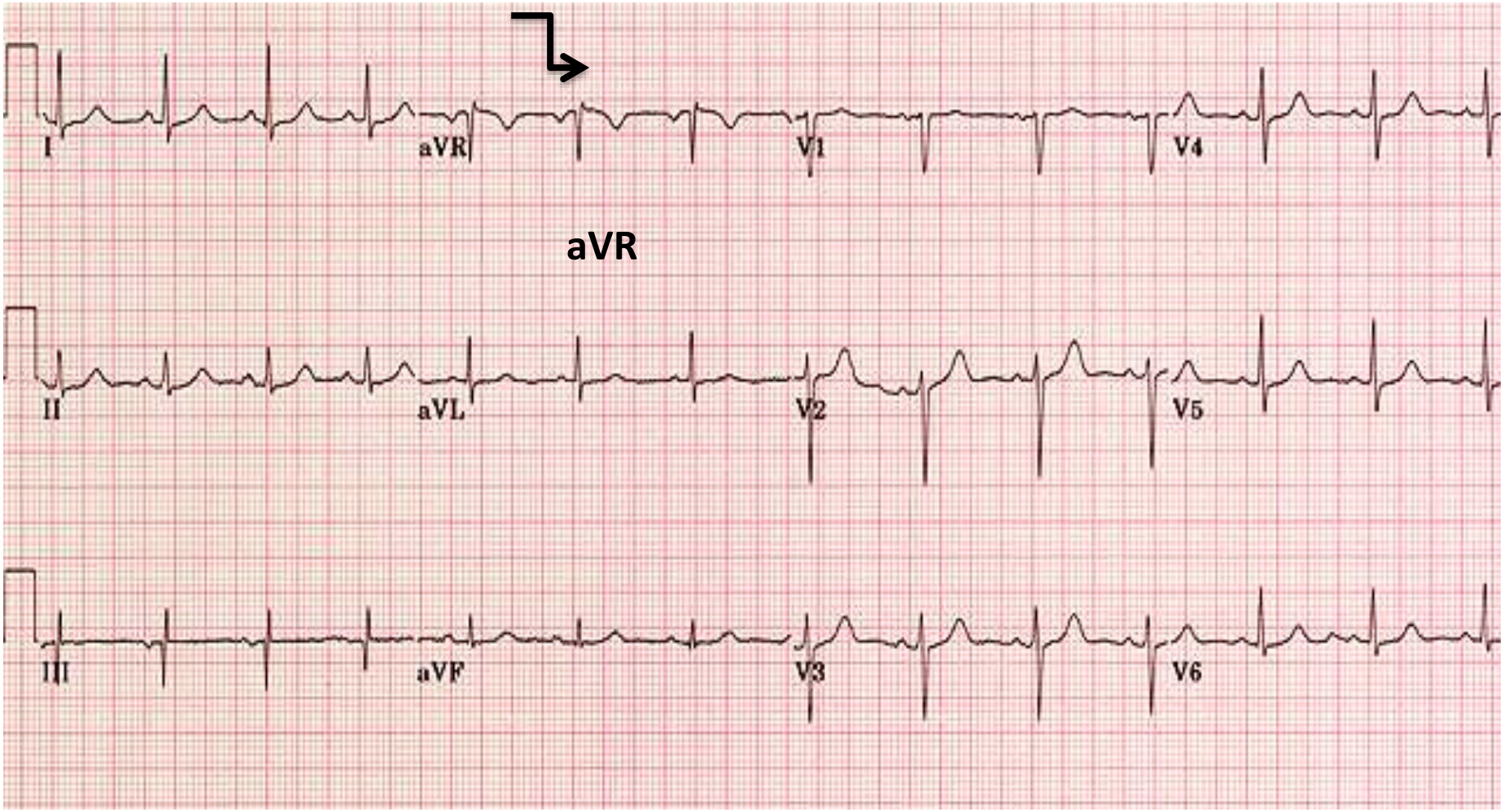

Respect aVR: The Neglected Lead

- The augmented unipolar leads are of low electrical potential and are thus instrumentally augmented – hence the prefix 'a'.
-
- The reference electrode is the mean of the potentials sensed by two of the three limb electrodes, with the exploring electrode being excluded from the reference electrode.
-
- Thus, lead aVR is the augmented unipolar right arm lead and may be considered as looking into the cavity of the heart from the right shoulder
- .
- It follows that all normally upright deflections on the ECG will, under normal circumstances, be negative in this lead

Respect aVR: The Neglected Lead

- The lead aVR is oriented to ‘look’ at the right upper side of the heart, and can provide specific information about the right ventricle outflow tract and basal part of the septum
- Traditionally, the limb lead with the tallest R wave has been used to determine the electrical axis of the heart. Another method to determine the electrical axis of the heart involves seeking the lead with the deepest negative deflection or S wave.
- If aVR were noted to have the deepest S wave, it follows that the electrical axis should be directly opposite the hexiaxial reference system, i.e., +30°

aVR in Axis Calculation

A

Classical limb lead display

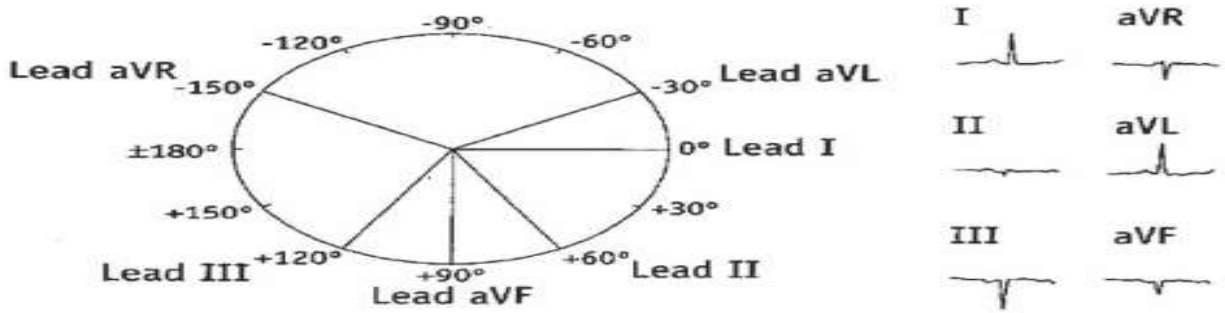

Directions of six limb leads used in classical display are indicated on *left*. Classical display of limb leads is indicated on *right*. Leads are shown in two separate sequences. First sequence consists of leads I, II, and III that are separated from each other by 60 degrees. Second sequence contains leads aVR, aVL, and aVF that are separated from each other by 120 degrees.

B

Orderly limb lead display

Directions of six limb leads used in orderly display are indicated on *left*. Orderly display of limb leads is indicated on *right*. All six limb leads are shown as one sequence with leads separated from each other by 30 degrees.

Respect aVR: The Neglected Lead

- The aVR is often neglected lead. It is an unipolar lead facing the right superior surface.
- As all the depolarizations are going away from lead aVR, all waves are negative in aVR (P, QRS, T) in normal sinus rhythm.
- In dextrocardia, (True and technical) the P is upright in aVR.

Dextrocardia

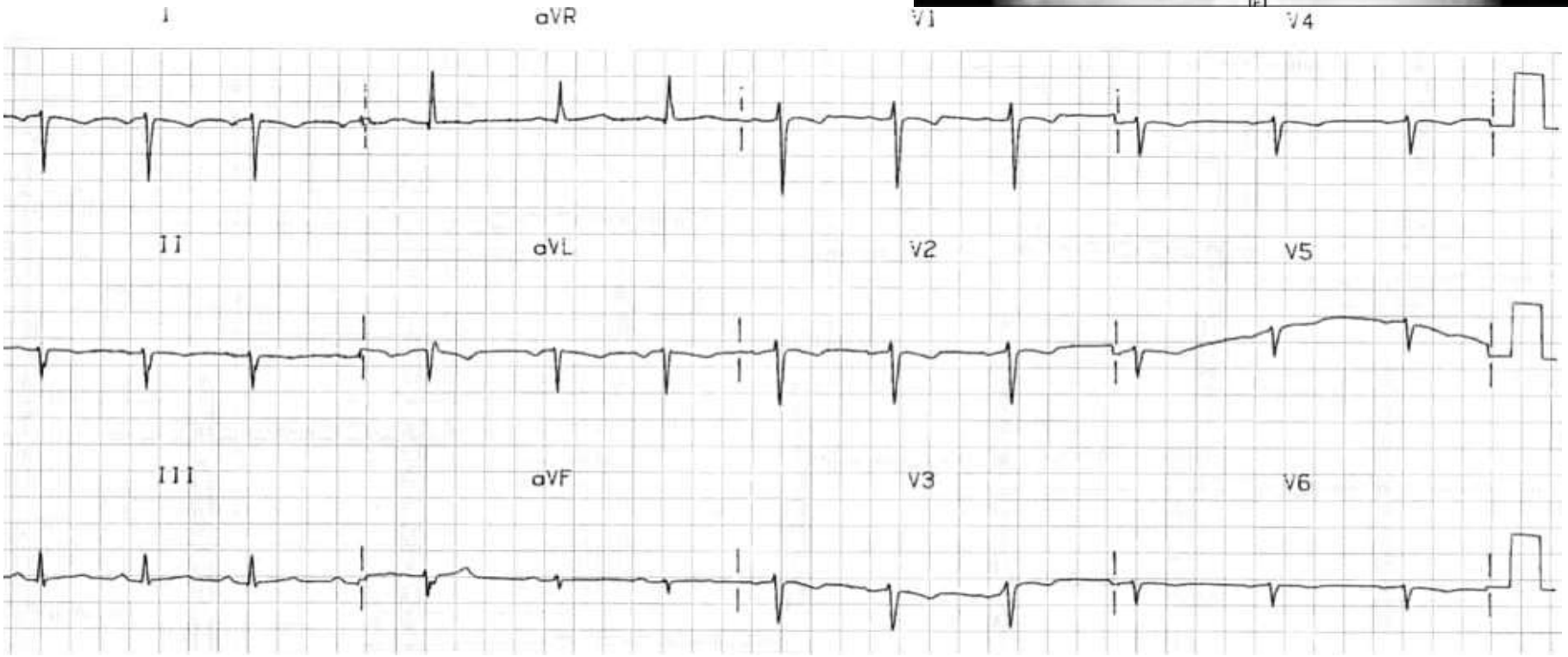

aVR: The Neglected Lead

- The lead aVR is a very important lead in localization of Coronary Artery Disease. In the presence of anterior ST elevation, ST elevation in lead aVR and V1 denotes proximal LAD obstruction where ST elevation is more in lead V1, than in aVR.
- In the presence of anterior ST depression, ST elevation in lead aVR indicates Left Main Coronary Artery (LMCA) Disease where ST elevation is more in aVR than in V1.

68 Yrs. Male brought to emergency with Severe chest pain with hypotension

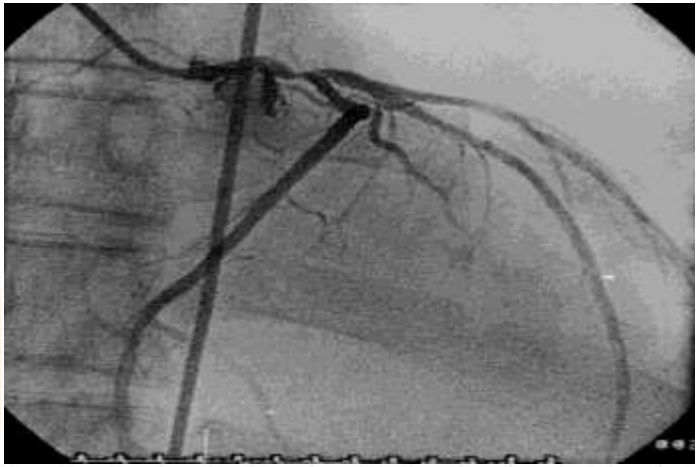

Left Main Stenosis

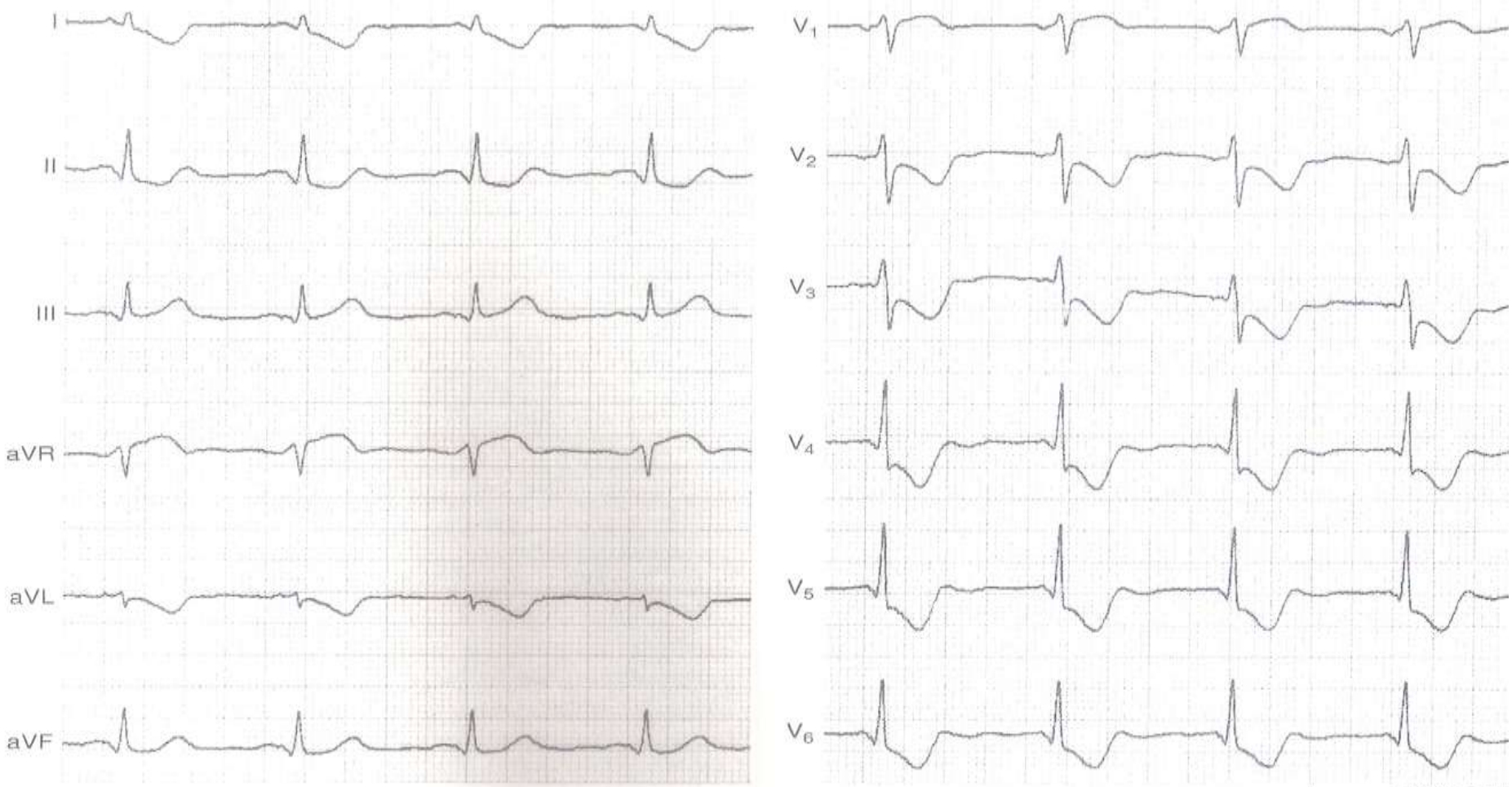

65 yrs Gentleman came to Emergency with severe Chest Pain

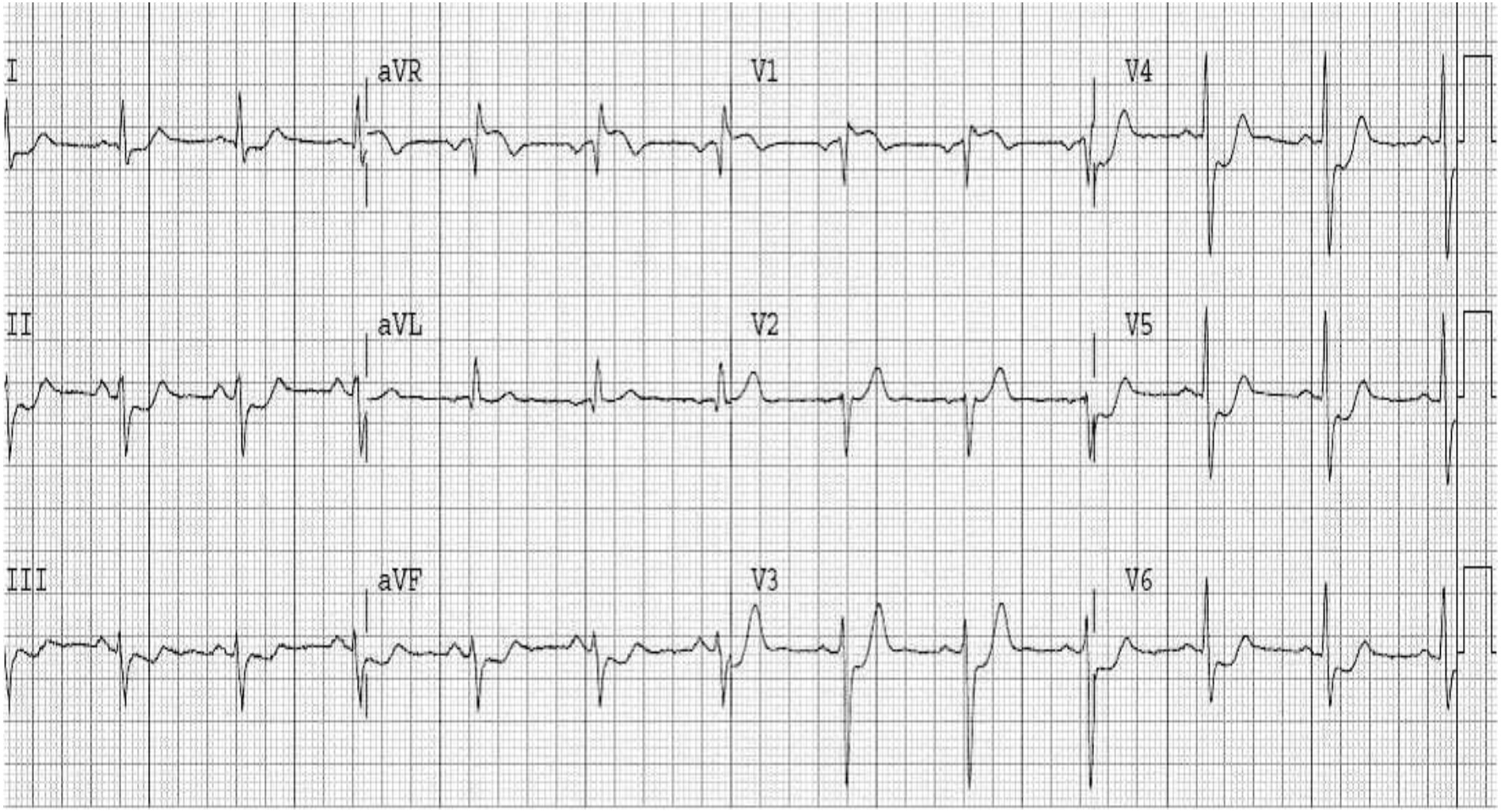

Critical Left Main Stem Stenosis

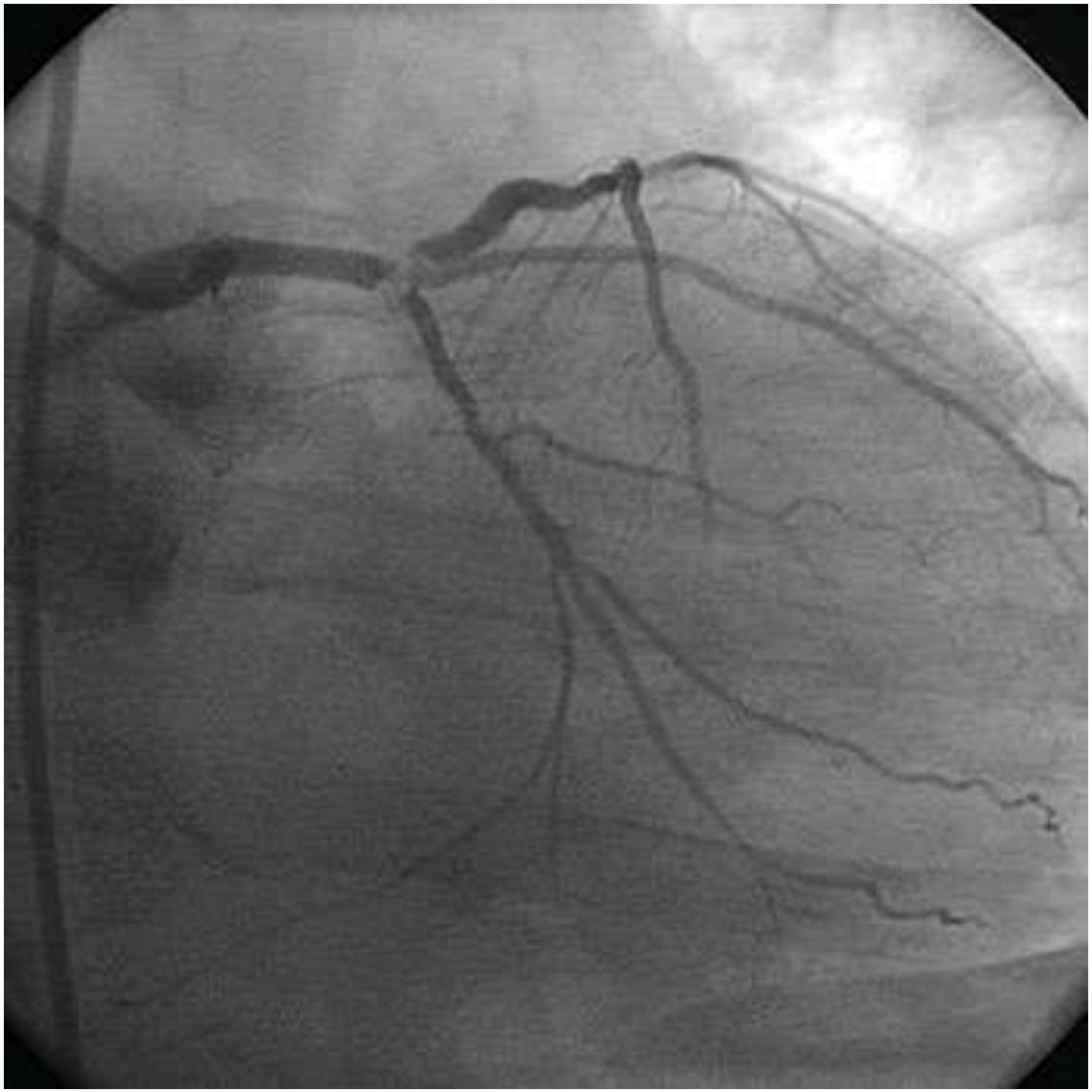

Critical Left Main Stem Stenosis

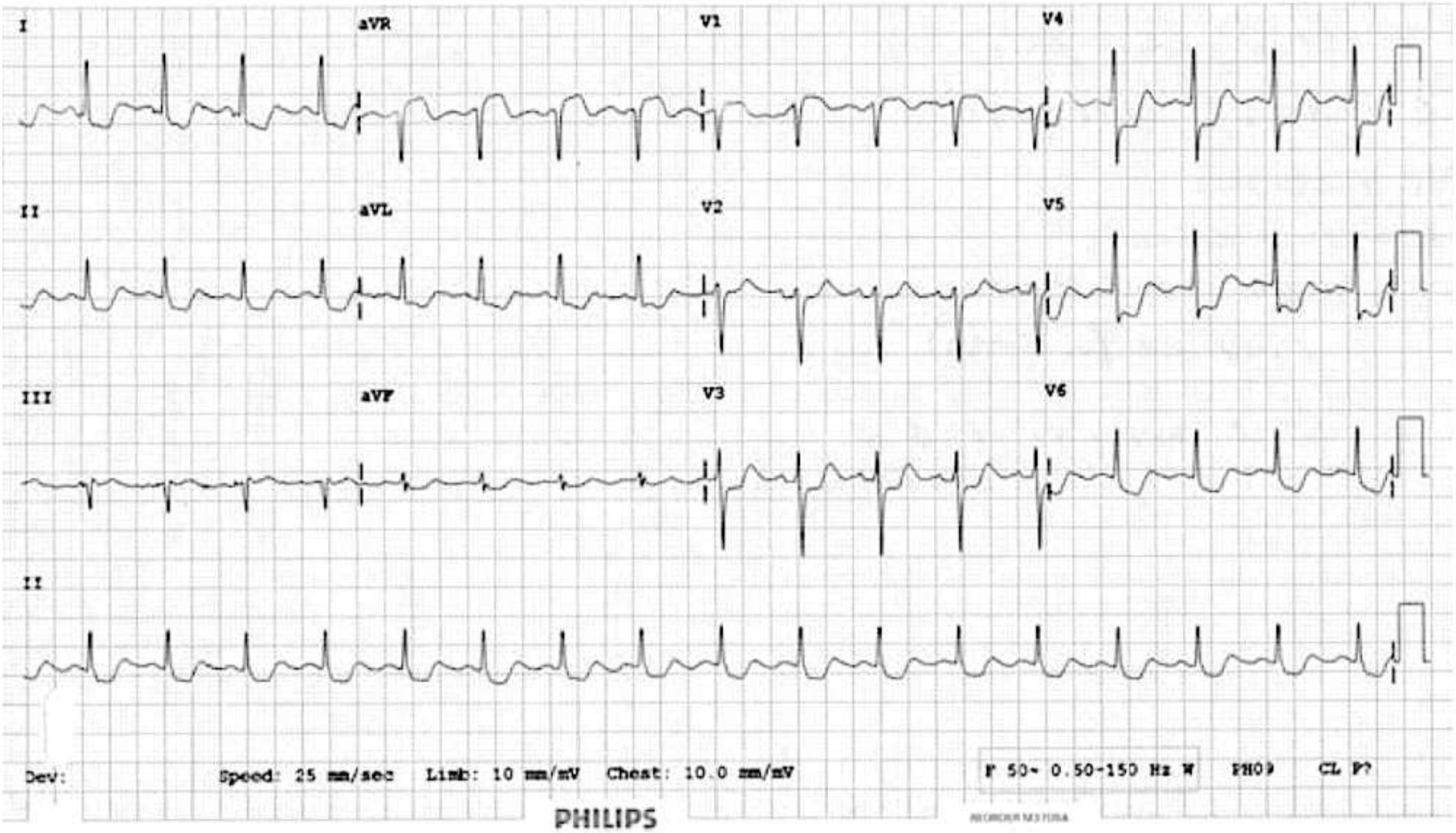

Left Main Stem

Acute Anterior Wall MI

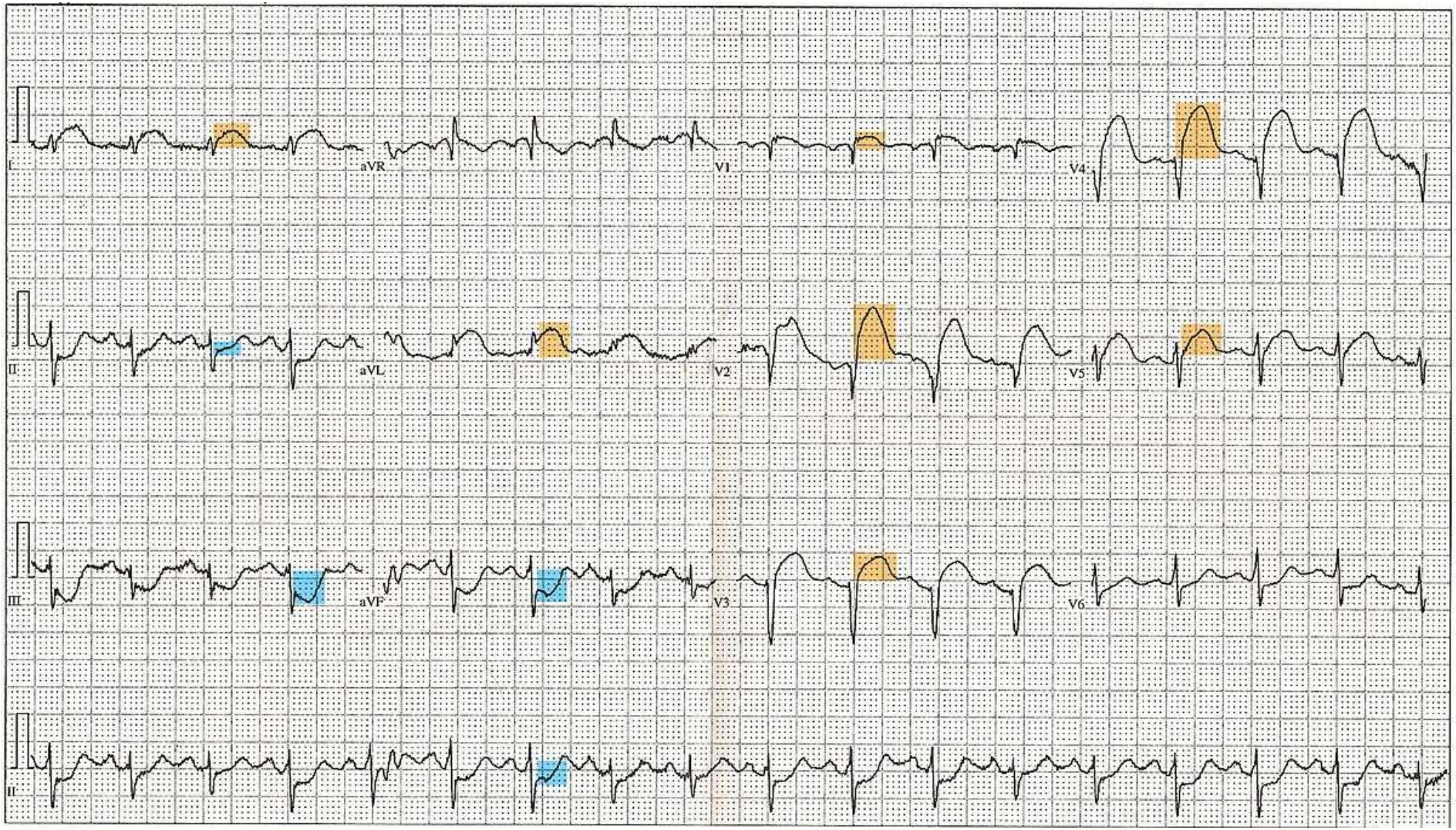

Coronary Angiogram

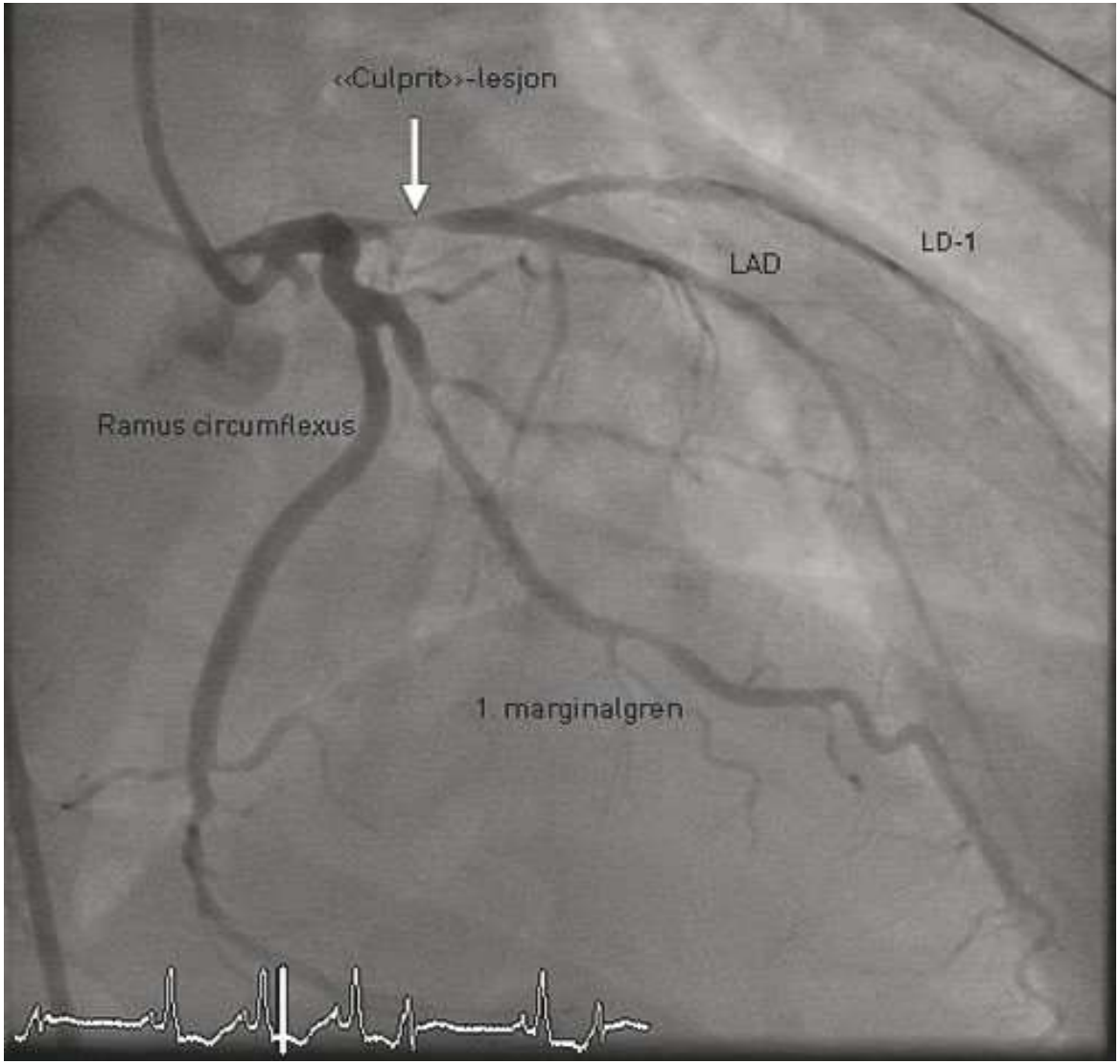

LAD Ostial Critical Blockage

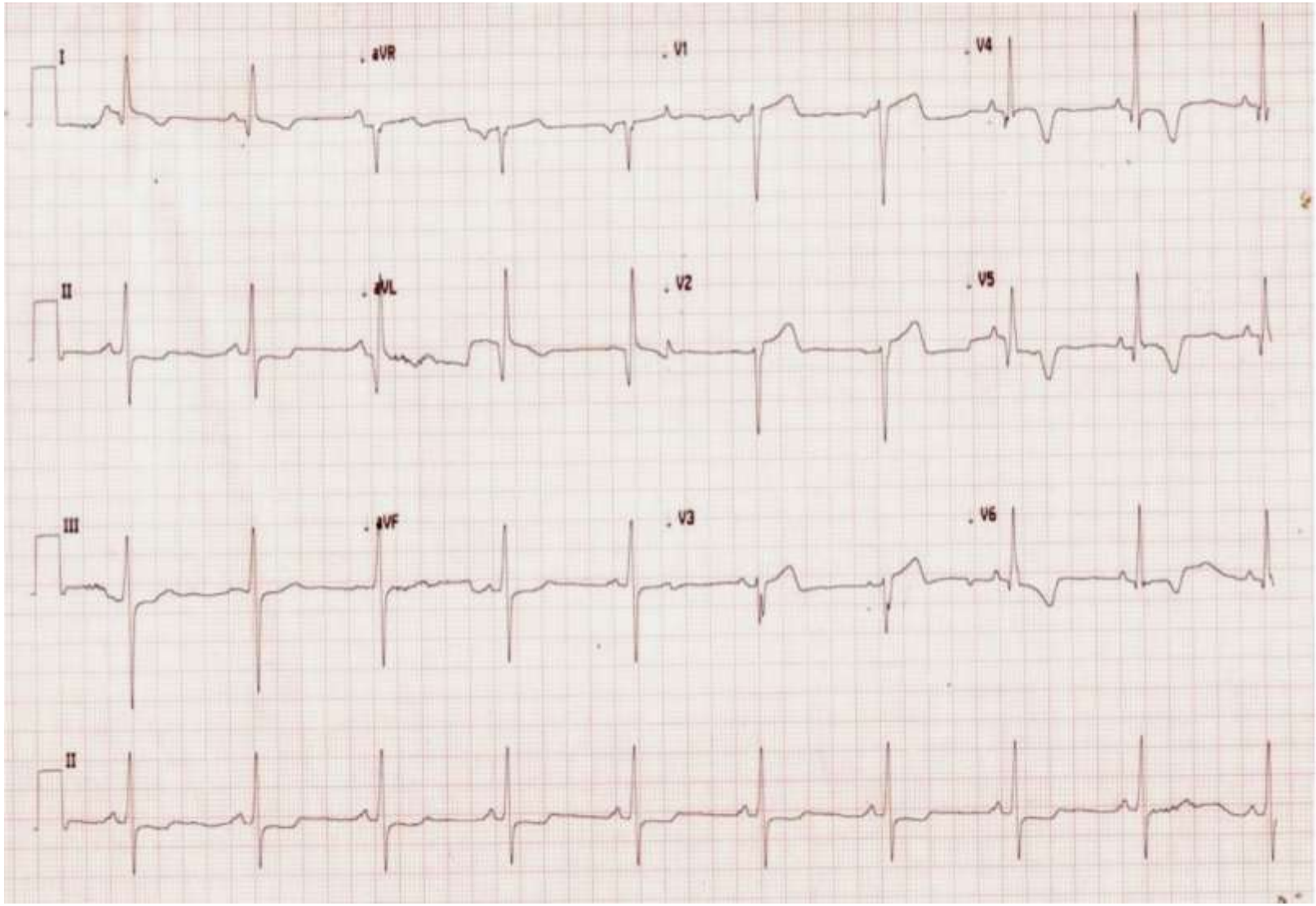

LAD Ostial Critical Stenosis

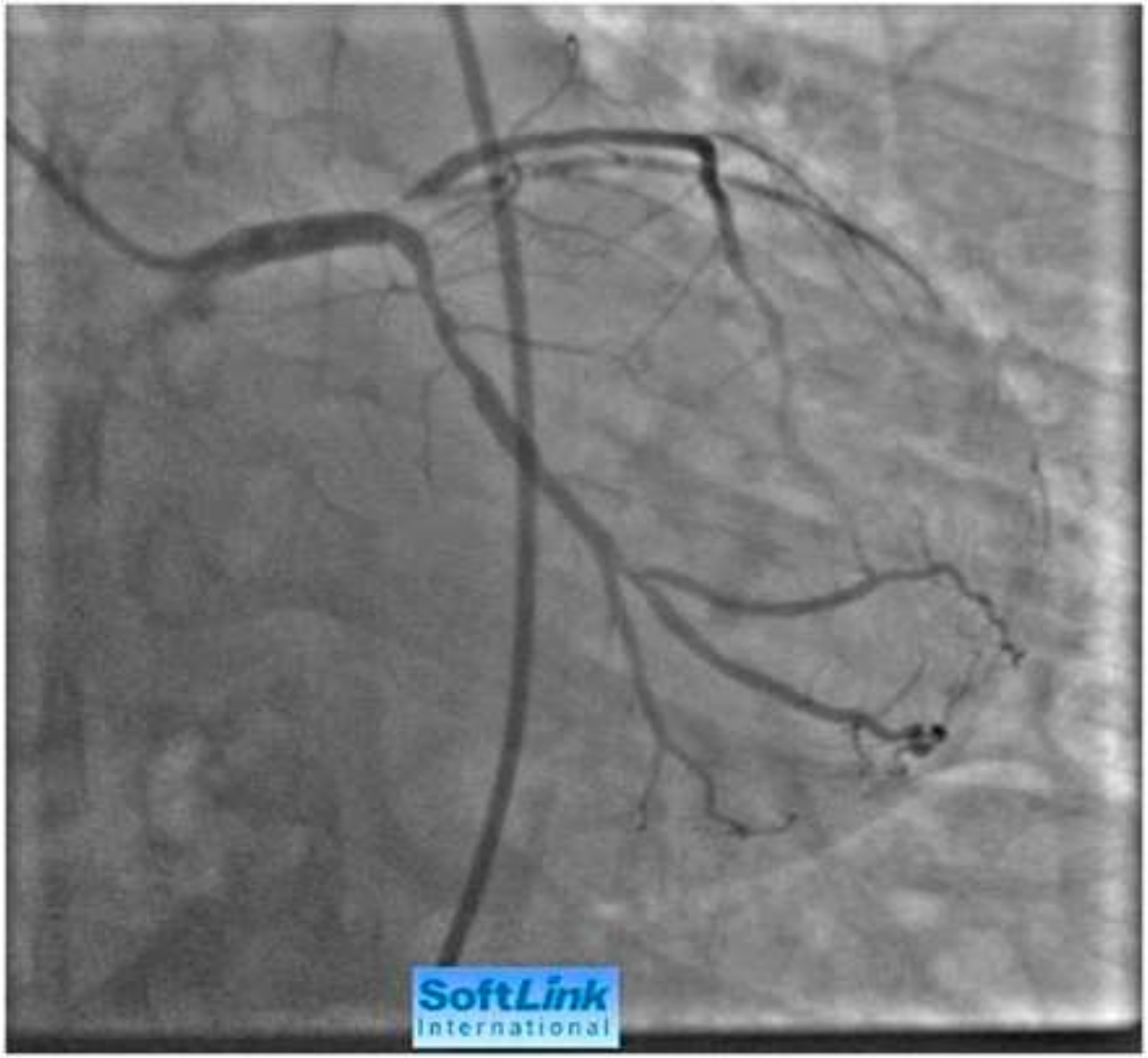

Where is the site of Blockage?

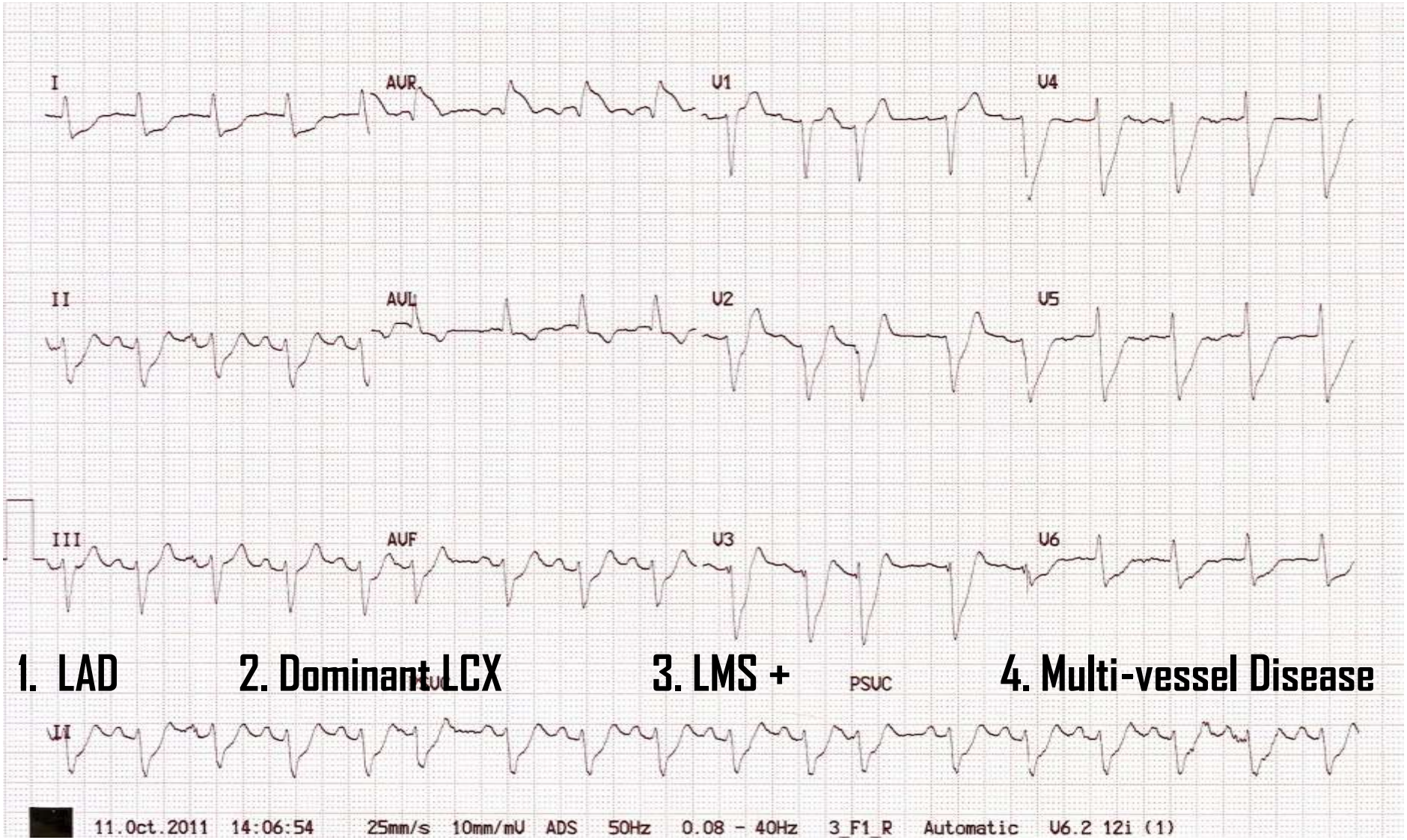

1. LAD
2. Dominant LCX
3. LMS +
4. Multi-vessel Disease

Left Main Stem and LAD Ostium

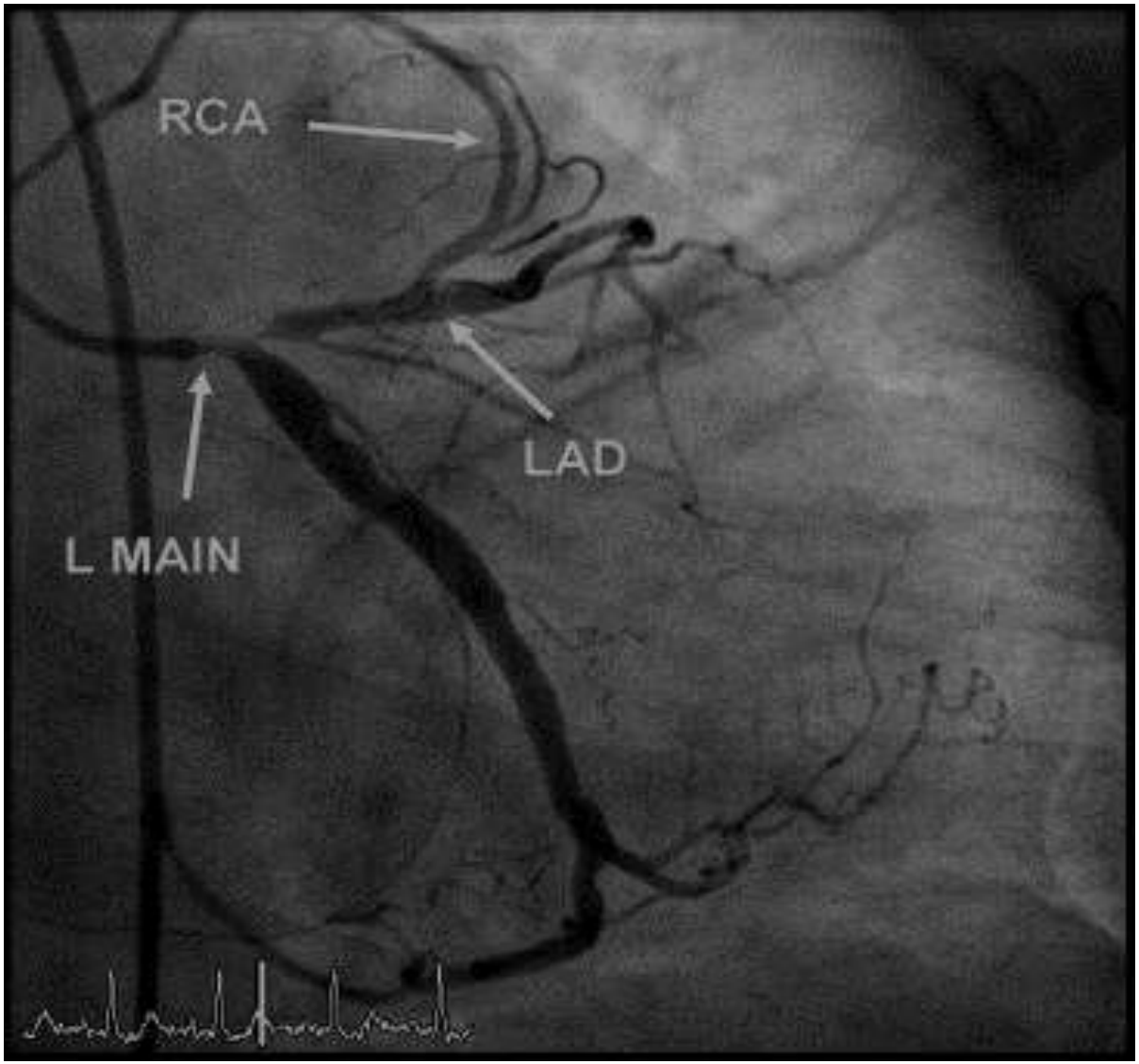

Such Critical Blockage may cause VT Storm

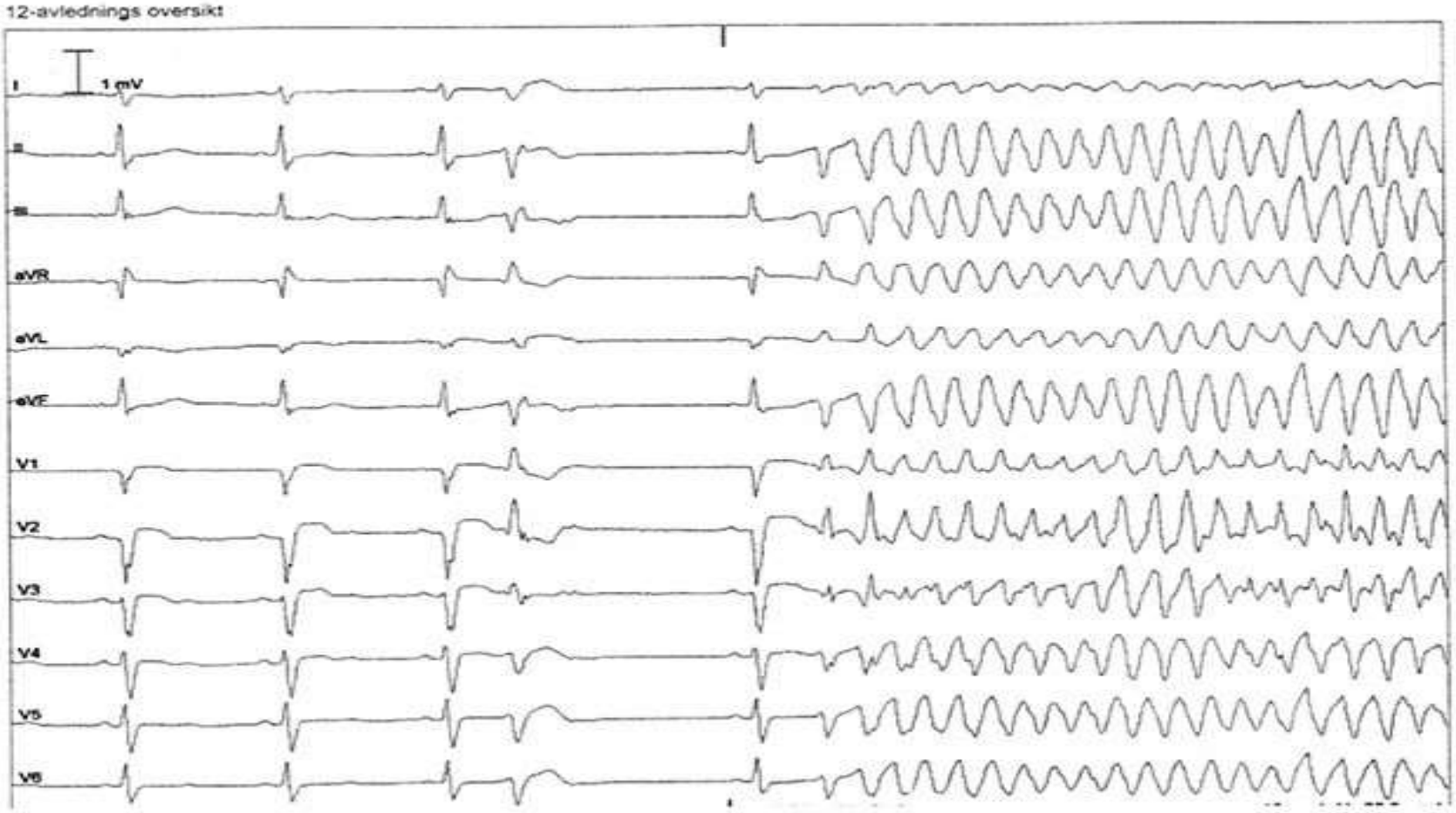

aVR: The Neglected Lead

- In wide QRS tachycardia, tall R wave in aVR indicates Ventricular Tachycardia rather than SVT with aberrancy

Wide QRS Tachycardia: SVT or VT?

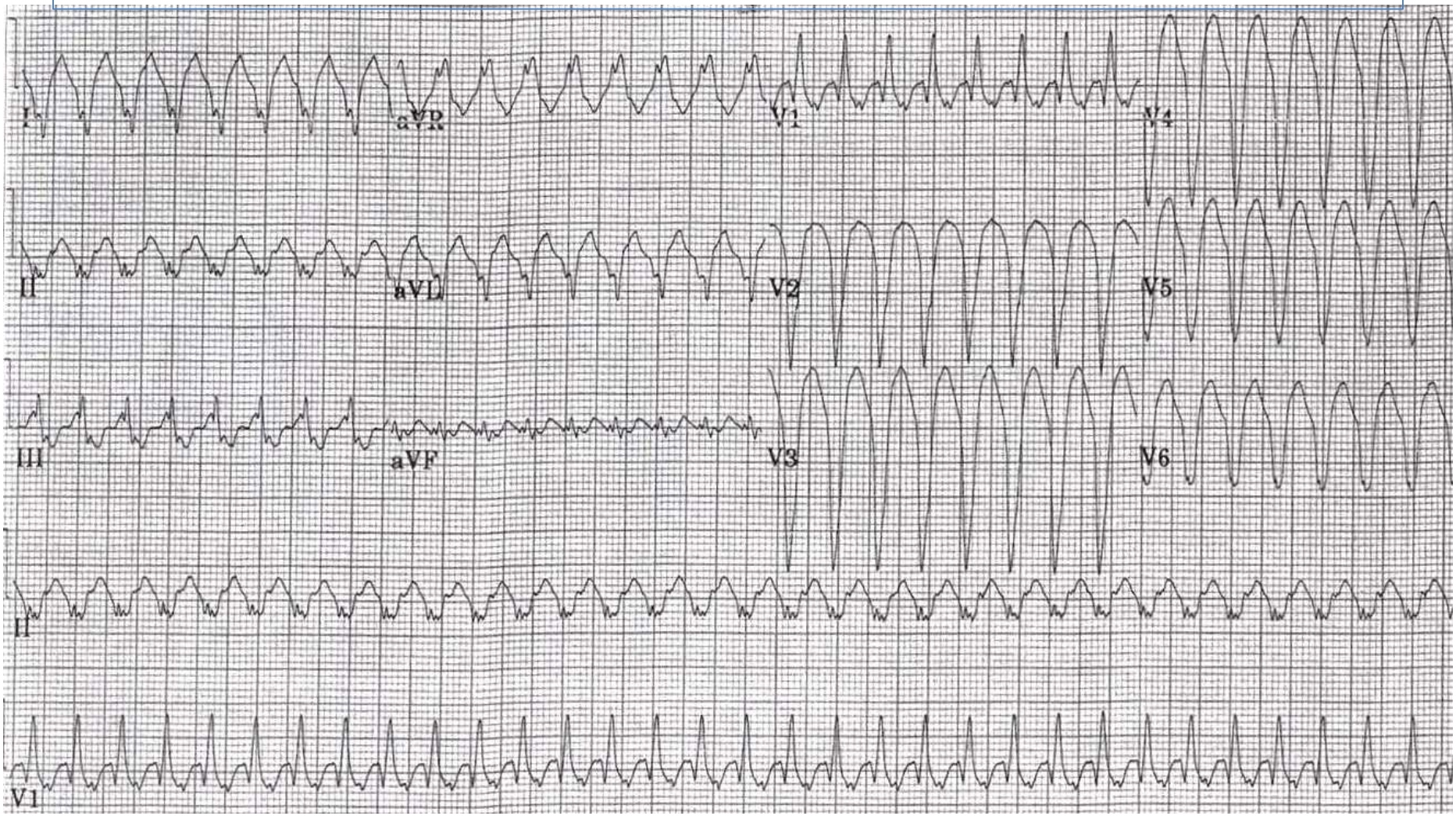

aVR: The Neglected Lead

- . In the presence of persistent ST elevation in anterior chest leads, the R in aVR is suggestive of left ventricular aneurysm (Goldburger's sign) or equiphasic QRS and initial R May suggest Ventricular Aneurysm

LV Apical Aneurysm: avR equiphasic

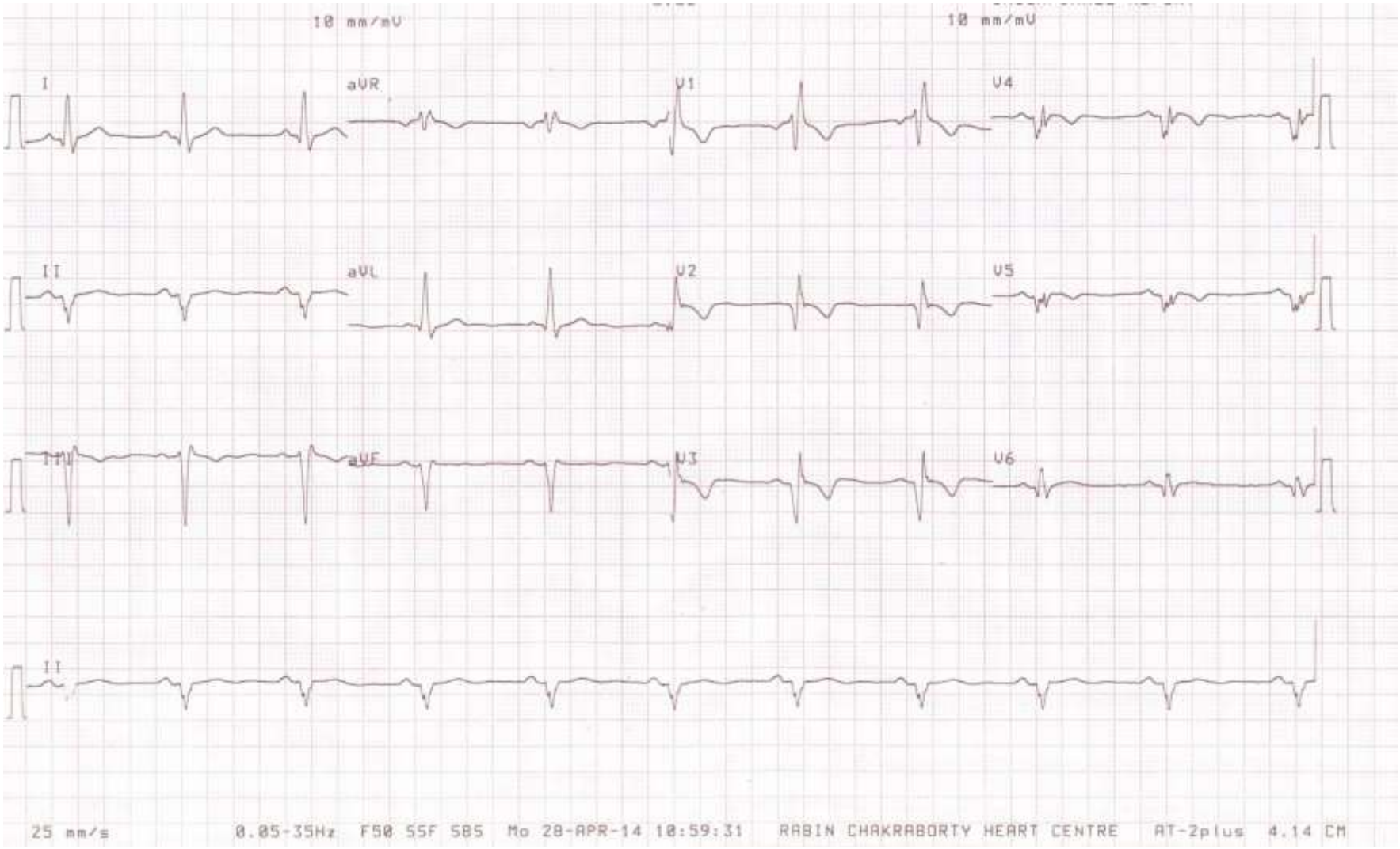

32 years Lady with recent heart failure and syncope

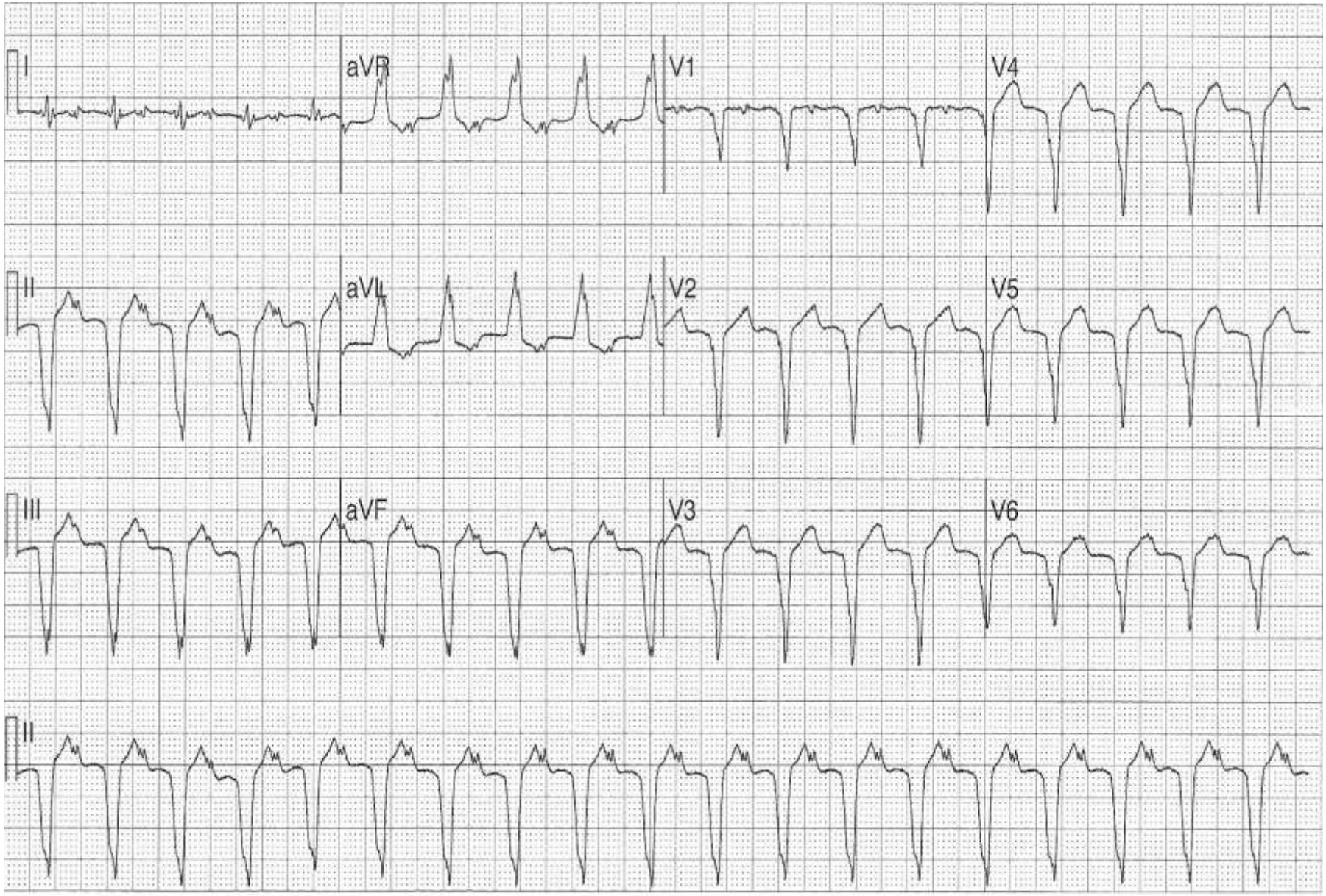

A Unique Case example

- This electrocardiogram (ECG) is from a 32-year-old female with recent-onset congestive heart failure and syncope.
- The ECG demonstrates a tachycardia with a 1:1 atrio:ventricular conduction. It is not clear from this tracing whether the atria are driving the ventricles (sinus tachycardia) or the ventricles are driving the atria (ventricular tachycardia).
- At first glance, sinus tachycardia in this ECG might be considered with severe conduction disease manifesting as marked first-degree atrioventricular block with left bundle branch block. Looking more closely, electrocardiographic morphology gives clues to the actual diagnosis of VT.
- These clues include the absence of RS complexes in the precordial leads, a QS pattern in V6, and an R wave in aVR. The patient proved to have an incessant VT associated with dilated cardiomyopathy.

This is the ECG of a young man with a structurally normal heart, and no chest pain.
What is the likely diagnosis?

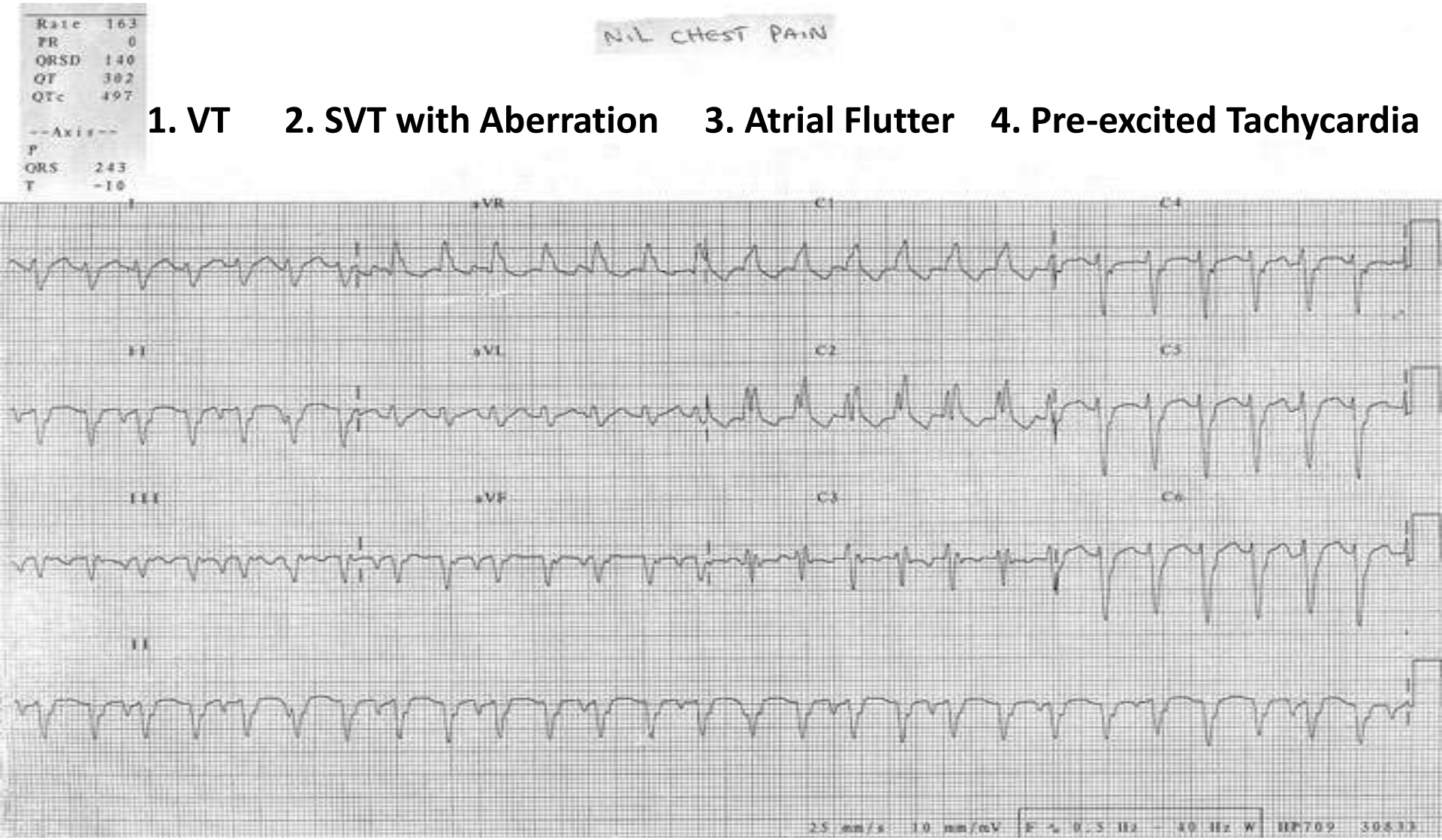

1. VT
2. SVT with Aberration
3. Atrial Flutter
4. Pre-excited Tachycardia

ST Segment Changes: Identifying MI Mimics

- **Acute Pericarditis**
  - T wave flattening or inversion
    - no T wave inversion during acute phase
    - uncomplicated pericarditis: negative T waves only occur in leads which usually have negative T waves (aVR & V_1)

ST Segment Changes: Identifying MI Mimics

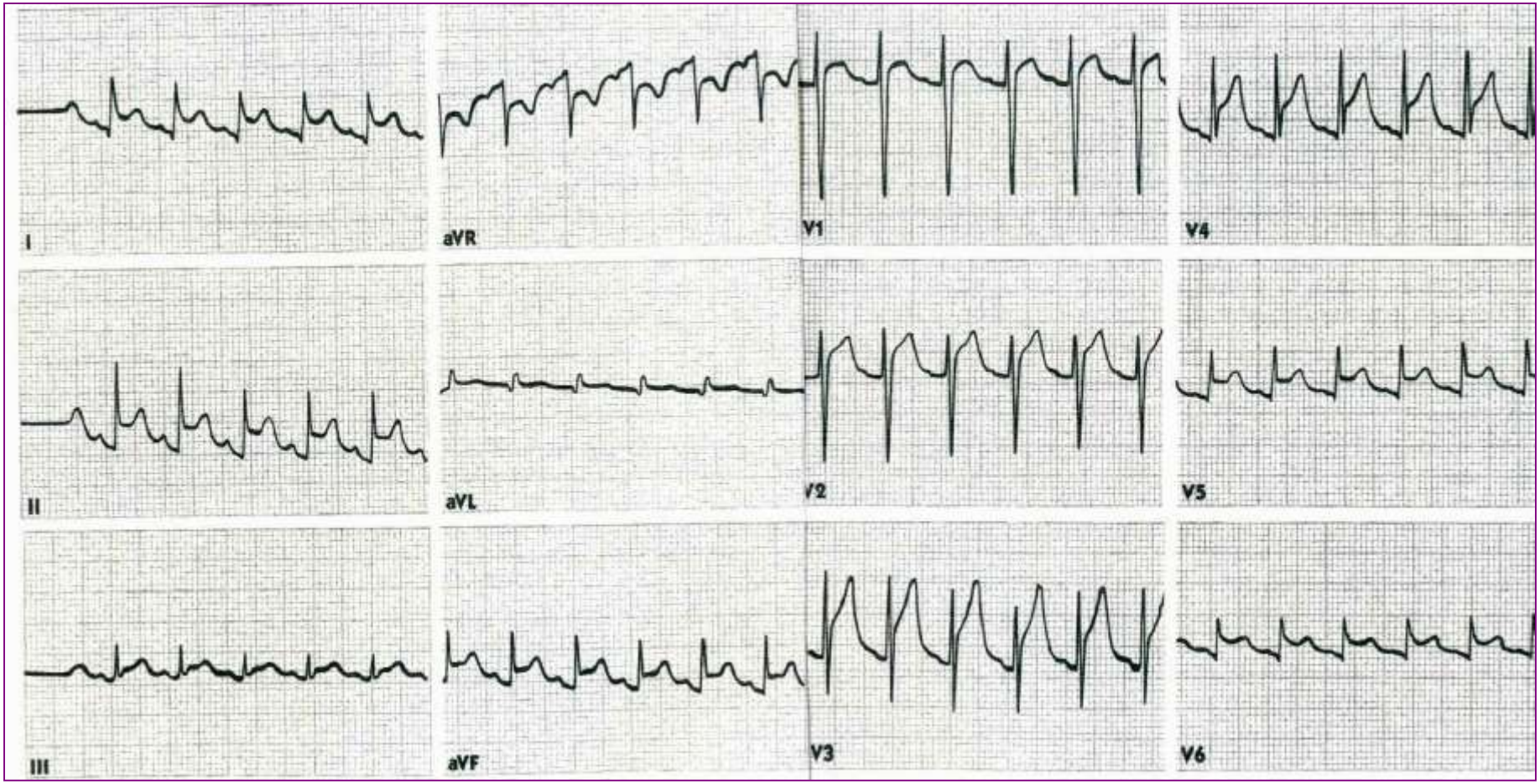

65 years Lady Post CABG, Chest Pain, ECHO – Pericarditis

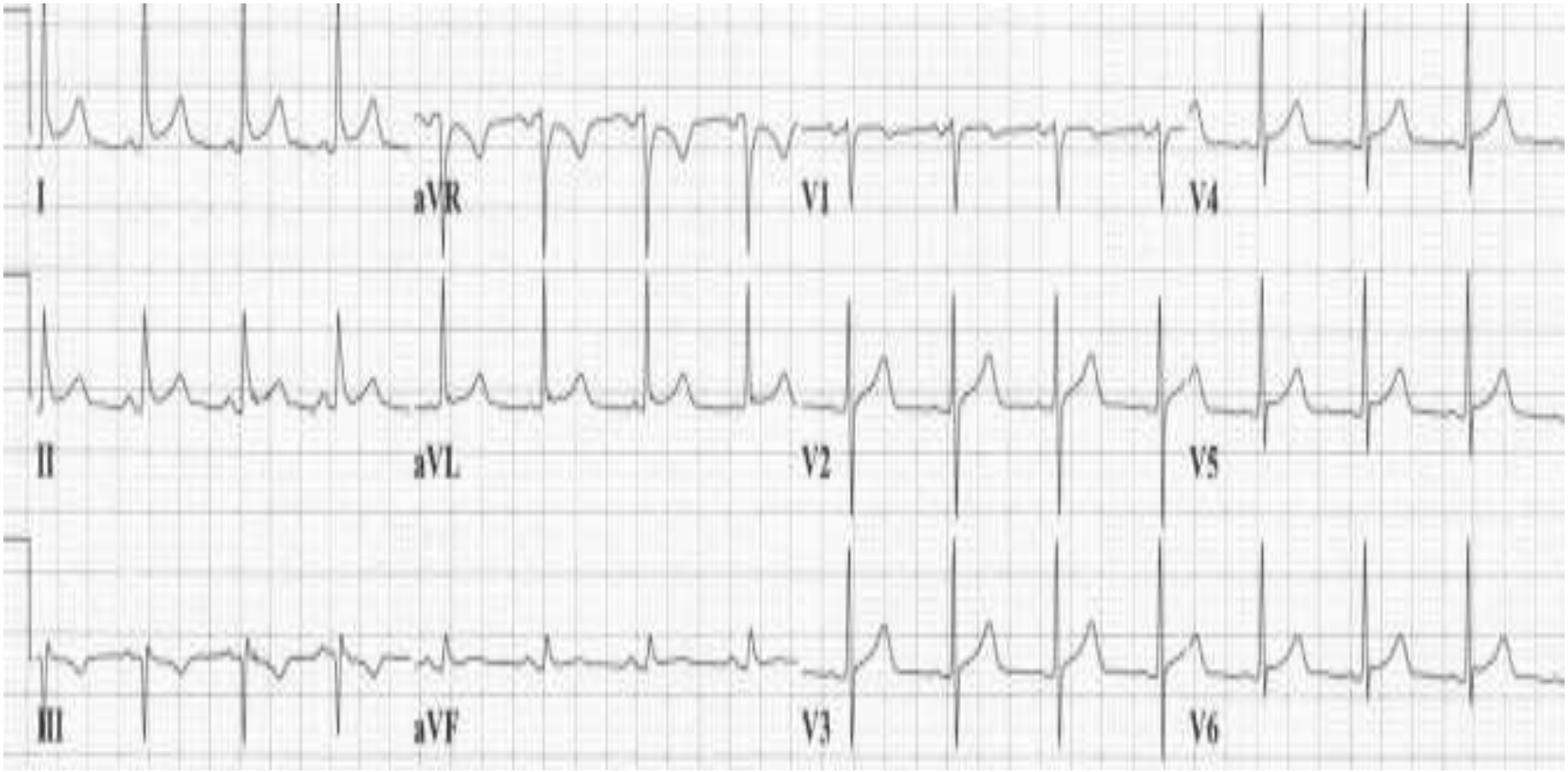

PR depressed in all and elevated in aVR, ST depressed in aVR

Acute Pulmonary Embolism

Acute pulmonary embolism distorts right heart hemodynamics and gives rise to a variety of ECG findings including the classic $S_1Q_3T_3$ pattern (S wave in lead I, Q wave in lead III and T wave inversion in lead III). ST segment elevation in aVR is believed to be due to acute right ventricular overload, transient hypoxia from impaired coronary flow or increased myocardial oxygen demand

Cardiac Arrhythmias and aVR

- The morphology of the P wave in lead aVR can be used to differentiate atrial tachyarrhythmias. A positive P wave in aVR during tachycardia favours atrioventricular nodal re-entrant tachycardia

- A negative P wave in aVR suggests a focal right atrial tachycardia

- ST segment elevation in aVR during narrow QRS complex tachycardia suggests atrioventricular re-entry through an accessory pathway as the mechanism of the tachycardia

aVR in AVNRT - +ve P (retrograde)

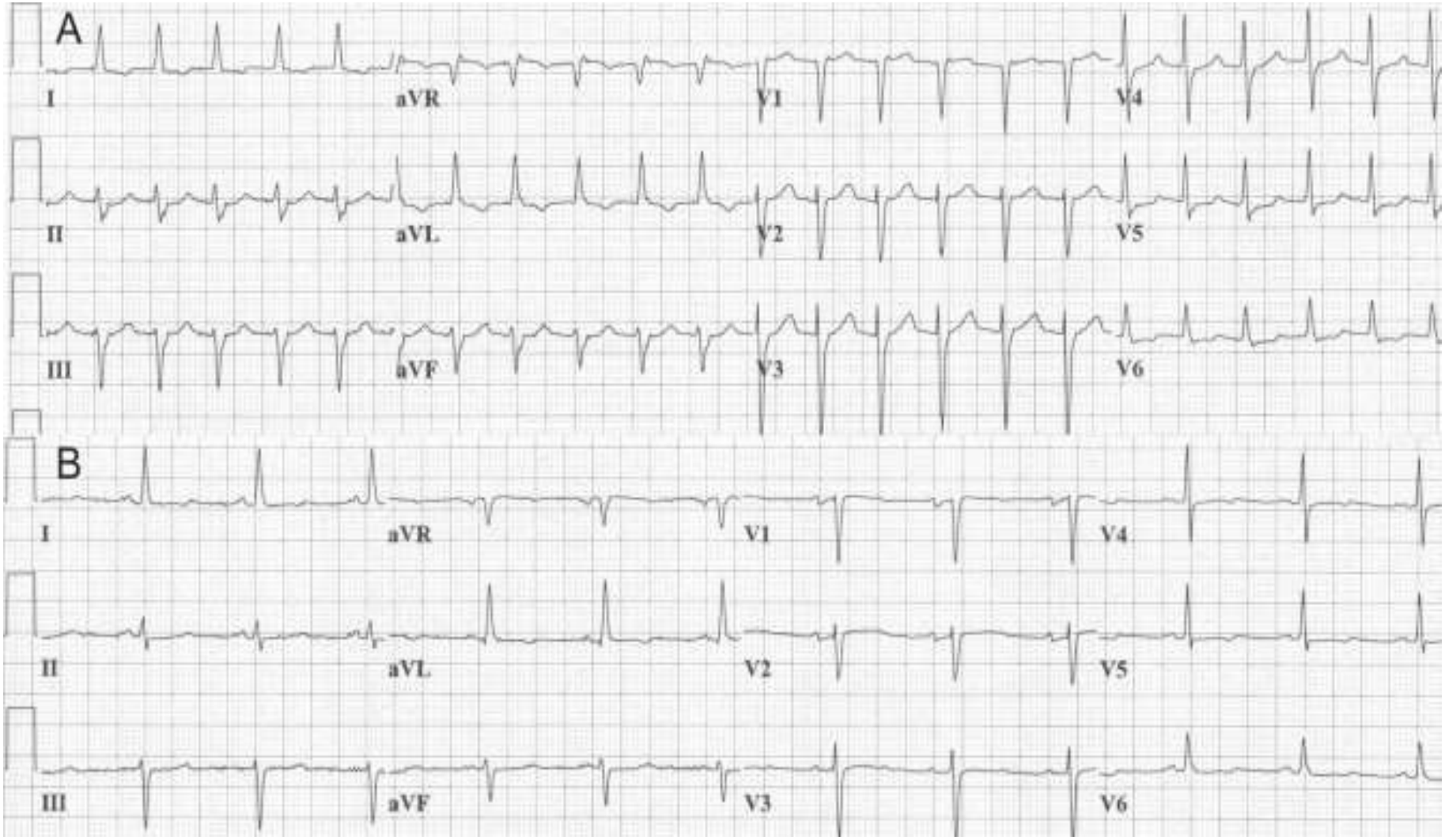

Atrial Tachycardia : -ve aVR, 2:1 Conduction

aVR in Brugada Syndrome: "aVR Sign"

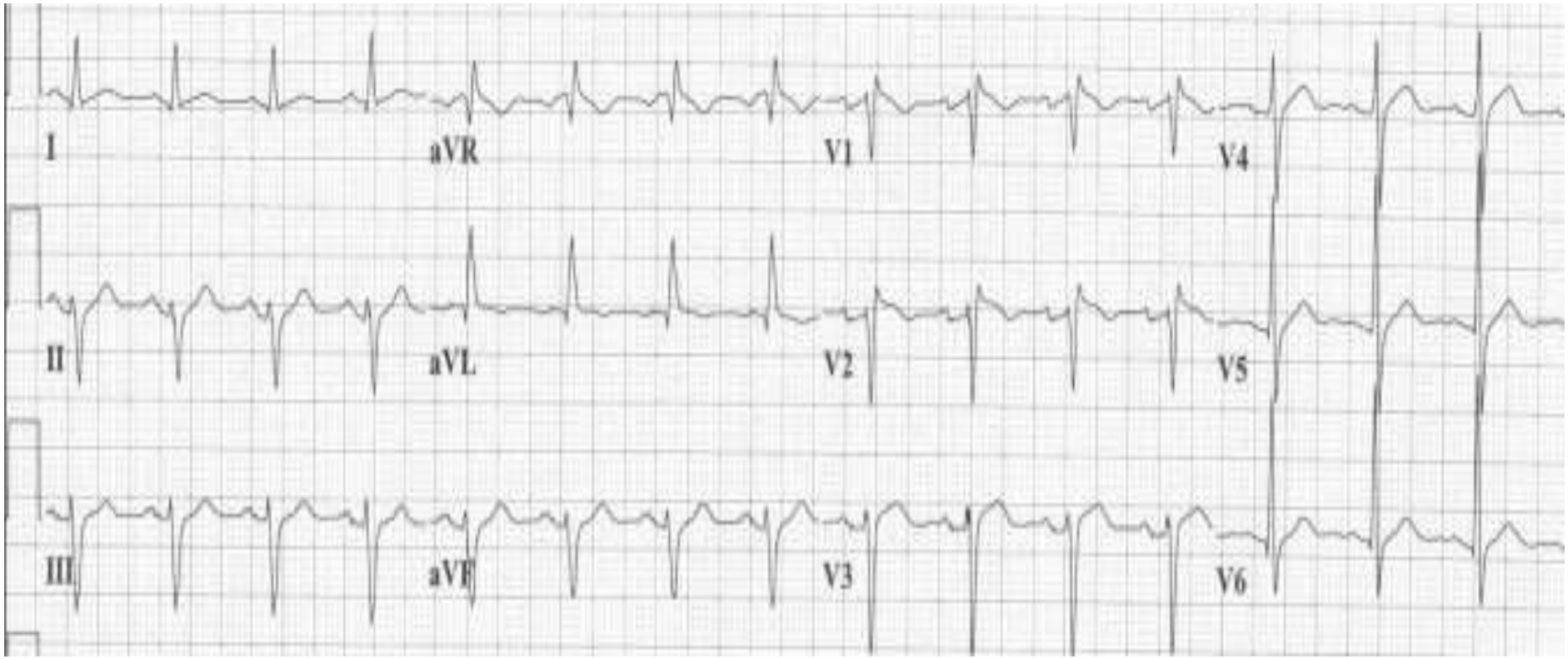

Electrocardiogram of a 46-year-old man with multiple syncopal episodes who was found on electrophysiological testing to have inducible ventricular fibrillation. Note the Brugada pattern in V_1 and V_2, and the 'aVR sign' (prominent R wave) in aVR

aVR and Tricyclic Antidepressant overdose

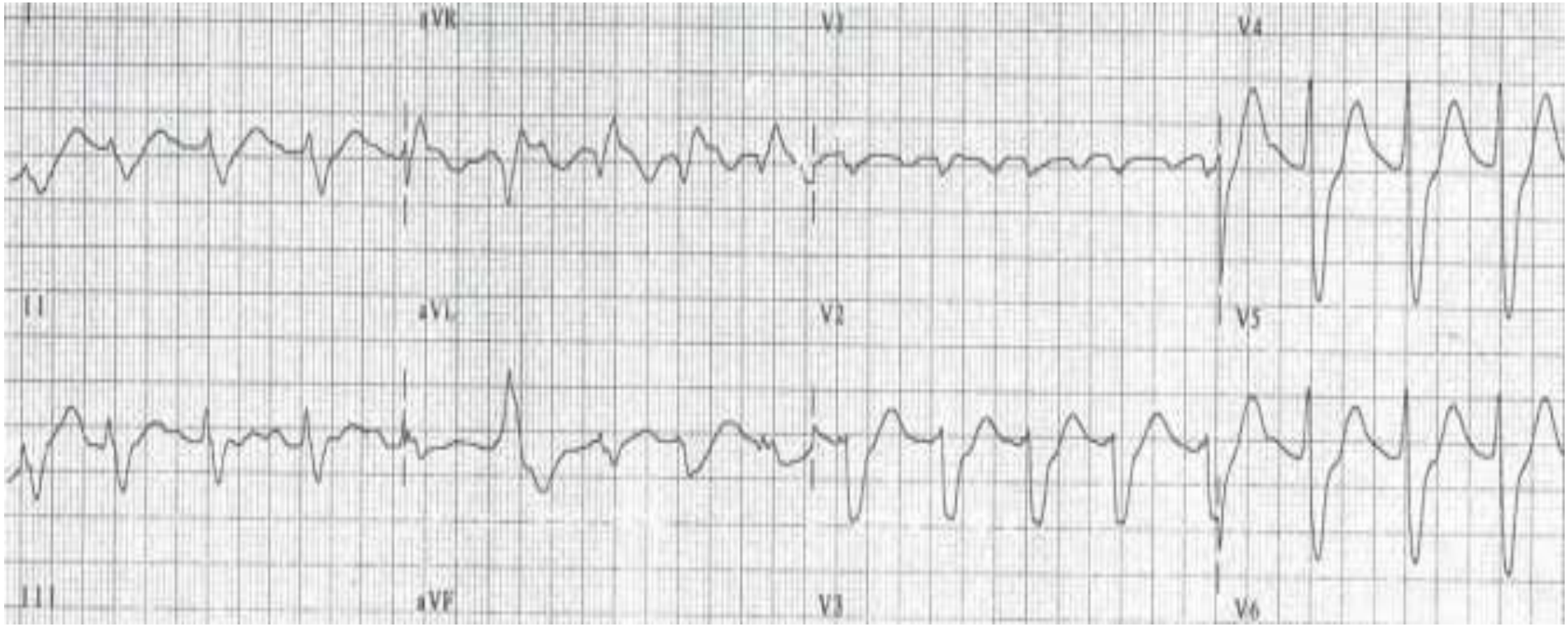

Electrocardiogram from a 39-year-old woman with a tricyclic antidepressant overdose. Note the sinus tachycardia, the QRS widening, the corrected QT prolongation and the 'terminal R wave' (R wave 3 mm or greater) in aVR. R/S ration in aVR is > 1

aVR in Left Anterior Hemiblock

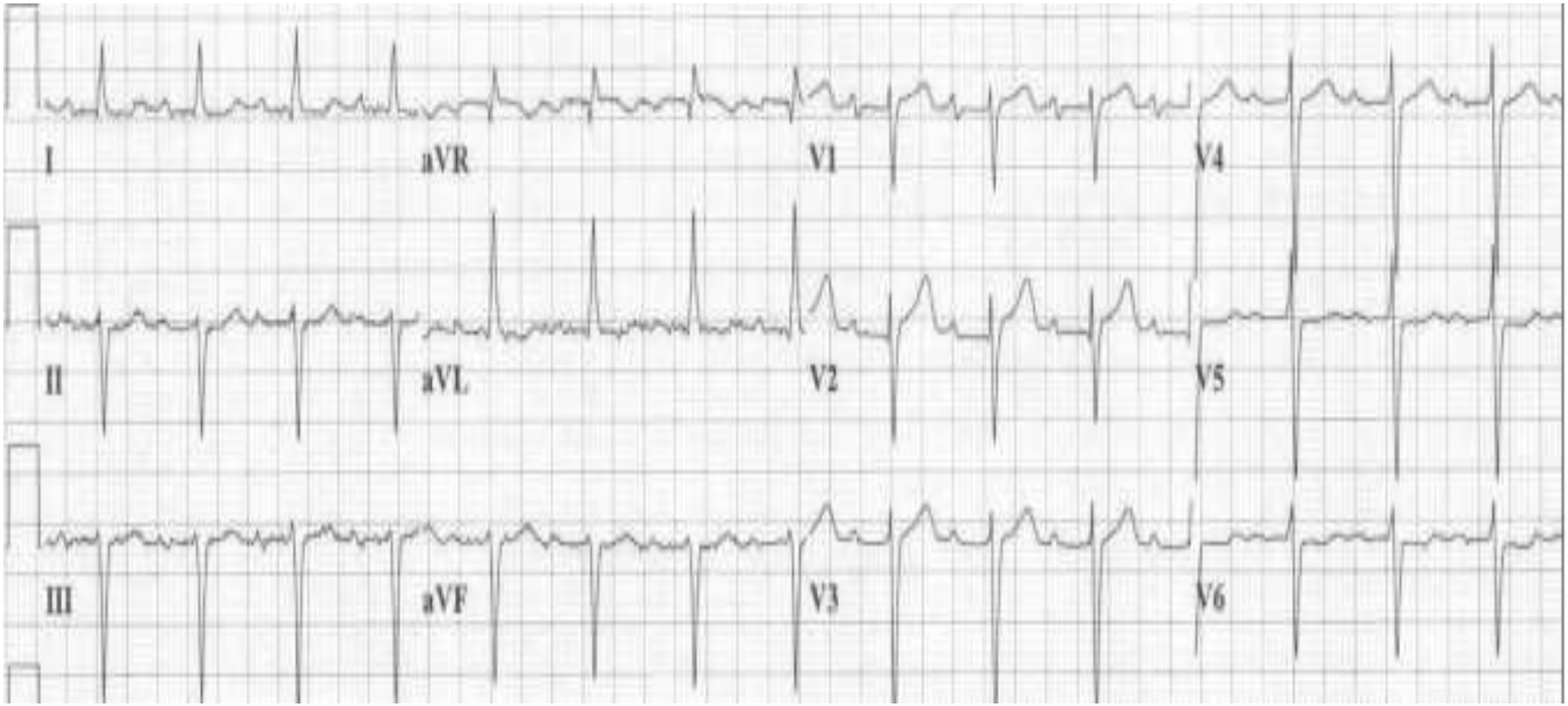

Warner et al, proposed new and improved electrocardiographic criteria for the diagnosis of left anterior hemiblock. They demonstrated a greater degree of accuracy in diagnosing left anterior hemiblock using criteria based on the fact that the peak of the terminal R wave in lead aVR occurs later than the peak of the terminal R wave in lead aVL, compared with using frontal plane QRS axis criteria

Warner RA, Hill NE, Mookherjee S, Smulyan H. Improved electrocardiographic criteria for the diagnosis of left anterior hemiblock. Am J Cardiol. 1983;51:723–6. [PubMed] [Google Scholar]

26 yrs Medical student asymptomatic routine ECG

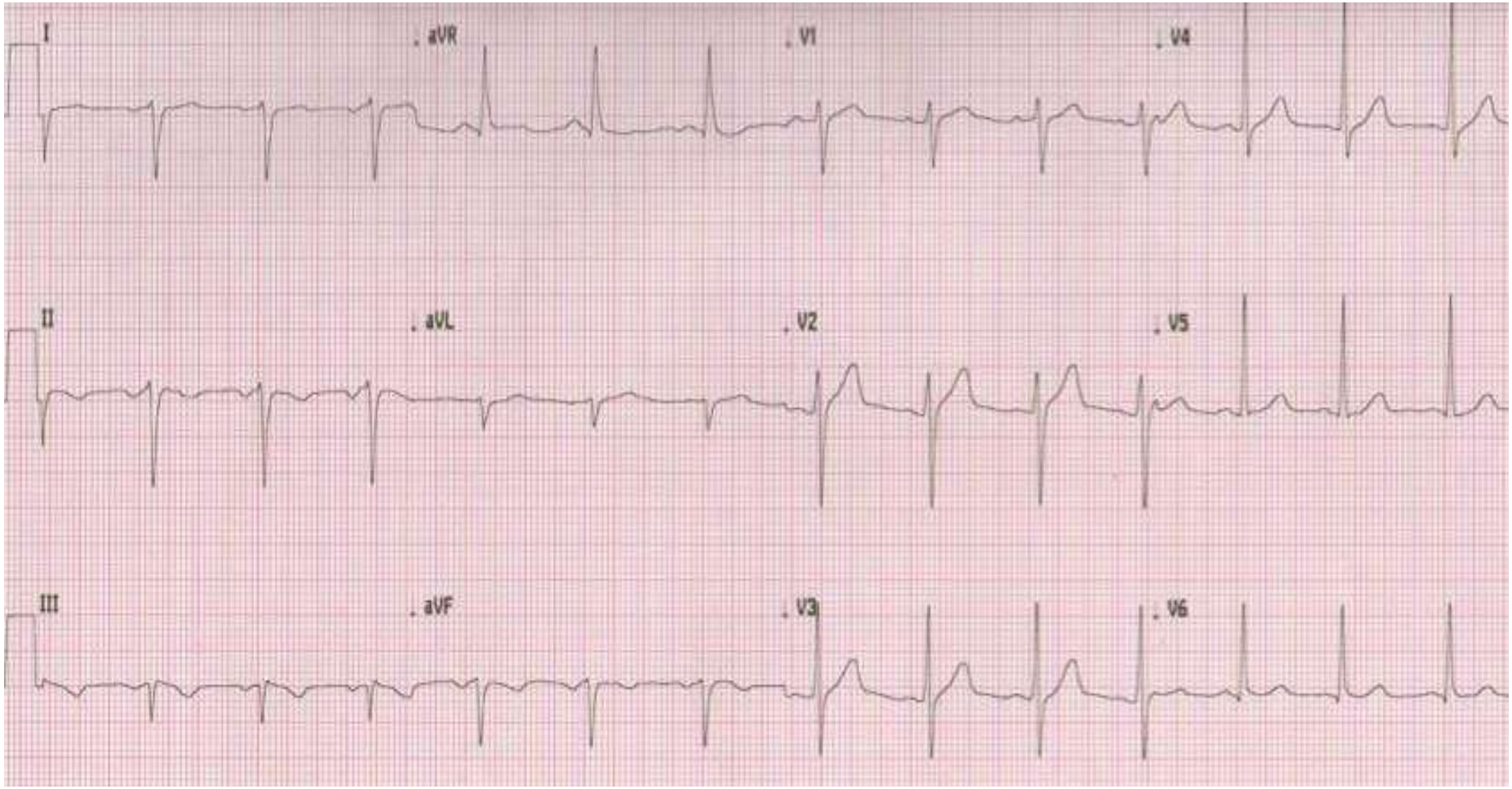

1. Dextrocardia
2. Lead Switch
3. Atrial Septal Defect
4. Rotation of Heart

Conclusion

- Lead aVR has multiple clinical applications and is a useful tool for interpreting ECGs. However, it is often overlooked, even by experienced ECG readers. Careful attention to this lead during evaluation of the ECG can aid in the diagnosis of acute LMCA or proximal LAD occlusion,
- Noting changes in aVR can aid in the diagnosis in clinical scenarios, including pulmonary embolism, tricyclic antidepressant overdose, dextrocardia and lead reversal.
- An interesting suggestion is to adopt an orderly, as opposed to classical, electrocardiographic limb lead display. They demonstrated that such a display results in greater diagnostic accuracy in less time.
- Nevertheless, aVR – the forgotten lead – can be a useful tool in the diagnosis and prognosis of many clinical syndromes.