Prof. Dr. Ketan K. Mehta (Mumbai)

MD (Med.), FCPS, FICP, FISE

***Asian Heart Institute**
***Suchak Hospital**
***Namaha Hospital**
***Lifeline Medicare Hospitals**

-Convenor: NATCON-2017
-Vice-President: IMA-Maharashtra State (2015-16)
-Treasurer : IMA – MW (2018-19)
-Org. Secy : MASTACON–2015
-Hon. Treasurer : ISE (2014-20)
-Hon. Jt. Secy : ICP (2013-14)
-Hon. Jt. Secy : NSPHERE (2010-18)
-Trust Board Member : MMA (2013-18)
-Hon. Treasurer : HSI (2004-06)
-President : MMA (2009-10)
-Org. Secy : Diamond APICON-2005
-President : AAME (2017-20)
-Expert Panel Member : MPOC
-Editorial Board Member : Journal of Medical Nutrition & Neutraceuticals

ST-T Changes : Nonspecific-Strain Vs Ischaemia

Basic Component : ST Segment

- The ST segment begins at the end of the QRS(J point) and ends at the onset of the T wave.
- Represents a state of unchanged polarisation between end of depolarisation and beginning of repolarisation or a stage when terminal depolaristaion and commencing repolarisation neutralise each other.
- It is normally isoelectric and deviation upto 0.1 mV is considered within normal limits.
- ST elevation/depression is measured with reference to the TP segment as isolelectric baseline.

"Changes of ST & T waves in ischemia & infarction are varied. Therefore, ECG changes should not be assessed without clinical back-ground"

Differential Diagnosis of ST depression

ST depression:

1. Ventricular hypertrophy
2. BBB
3. Drugs & Electrolytes (Hypokalemia)
4. Cardiomyopathy

Type of ST depression:

1. Upsloping
2. Flat
3. Downsloping

The types of ST segment depression in the patient with acute coronary ischaemic syndrome and no evidence of infarction.
(A) Horizontal. (B) Downsloping. (C) Upsloping

Emerg Med J 2002;19:129–135

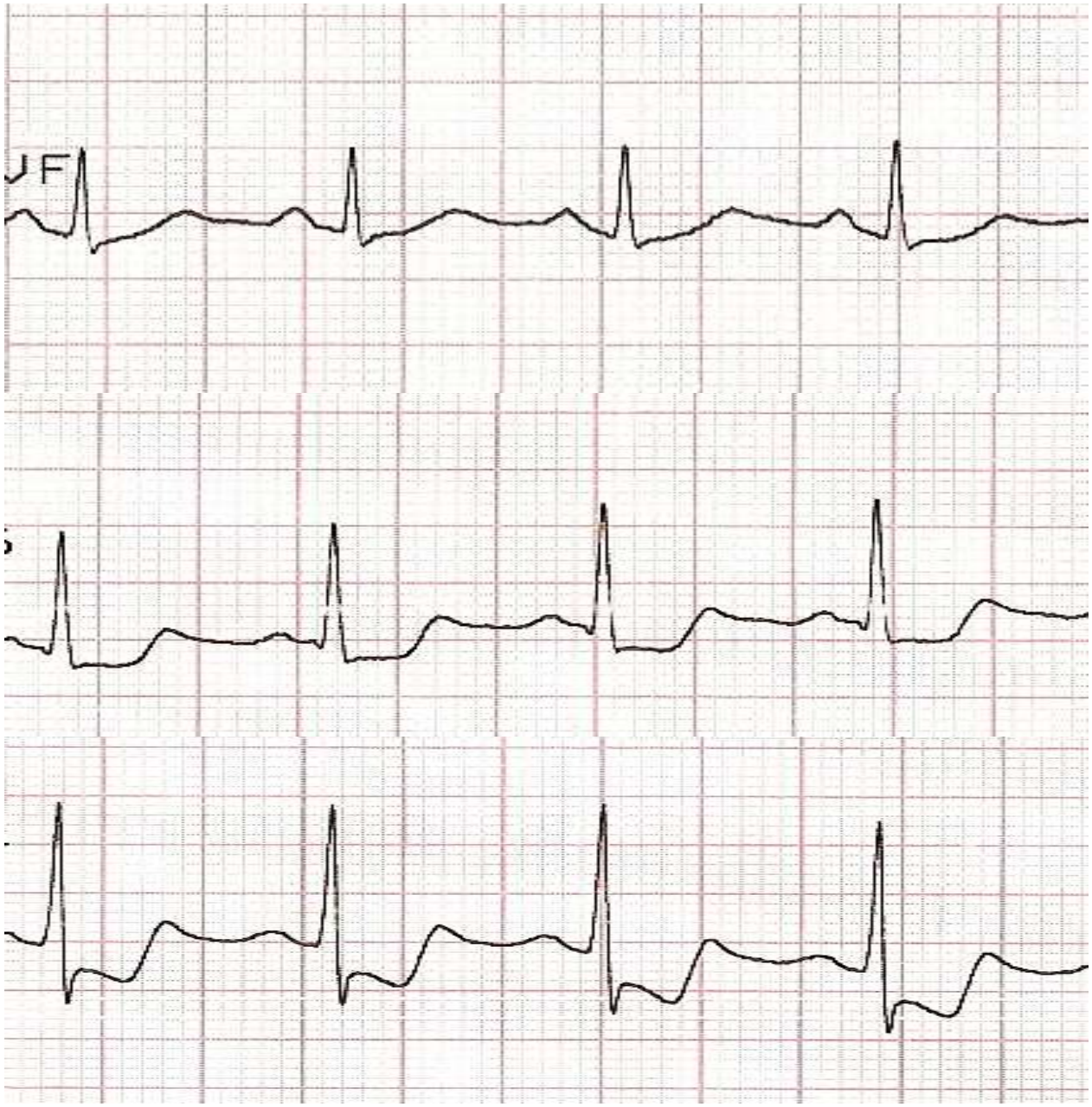

Flat or downsloping ST depression more specific for ischemia & poor prognostic sign

Inverted T waves

Routine interpretation of symmetrically or deeply inverted T waves as a sign of myocardial ischaemia without considering other possibilities is one of the most common errors in electrocardiography, often leading to undesirable consequences

T Inversion

Differential diagnosis:

1. Ischemia
2. Ventricular hypertrophy
3. BBB
4. Myocarditis
5. Hypertrophic cardiomyopathy
6. CVA (intra-cranial hemorrhage)
7. Non-specific

Symmetrical arrow-head T inversion (>0.2mv in depth) are more specific for ischemia

T wave inversion may be considered to be evidence of myocardial ischaemia if:

- At least 1 mm deep
- Present in ≥ 2 continuous leads that have dominant R waves (R/S ratio > 1)
- Dynamic — not present on old ECG or changing over time

T wave inversion is only significant if seen in leads with upright QRS complexes (dominant R waves).

T wave inversion is a normal variant in leads III, aVR and V1.

T Inversion

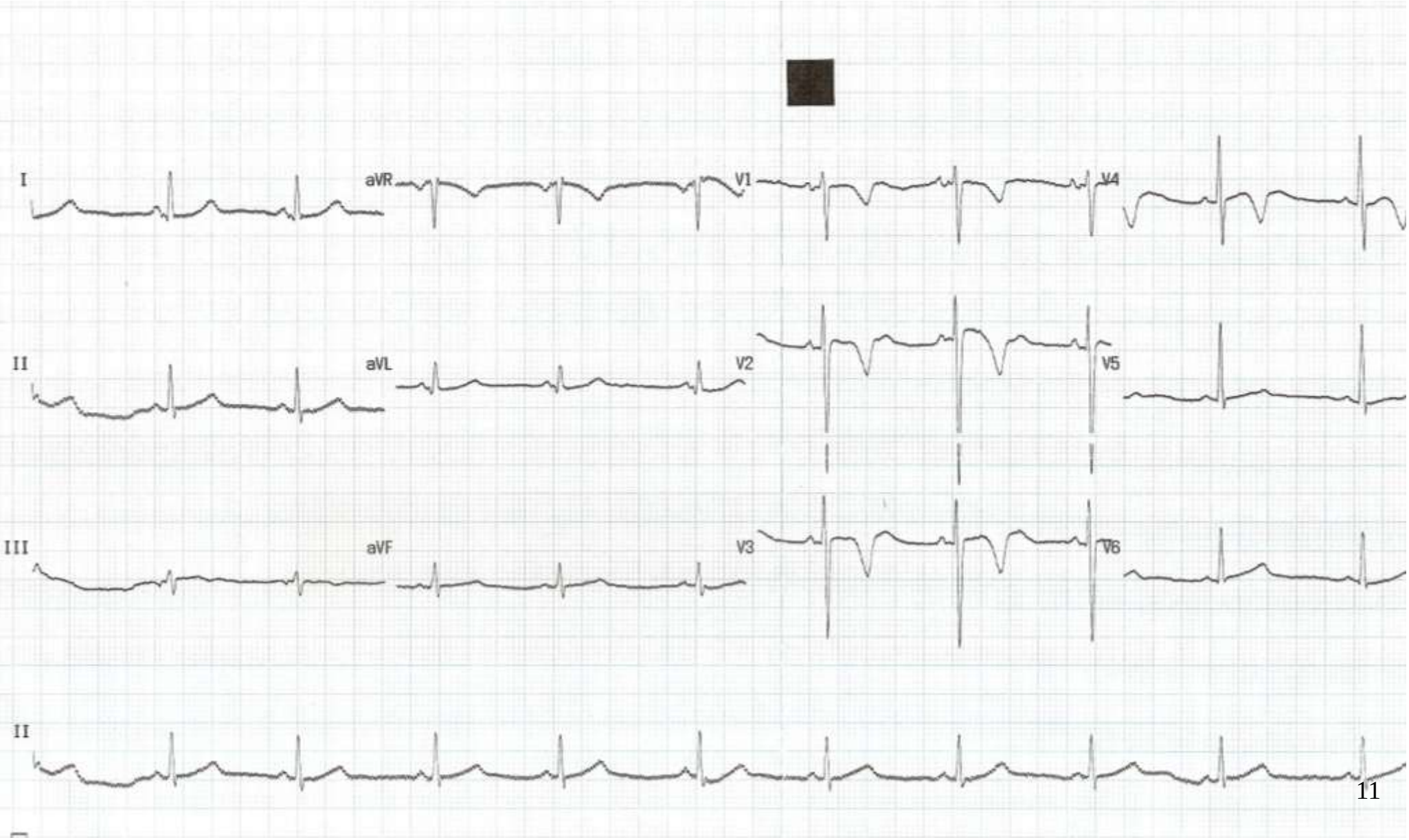

T Inversion

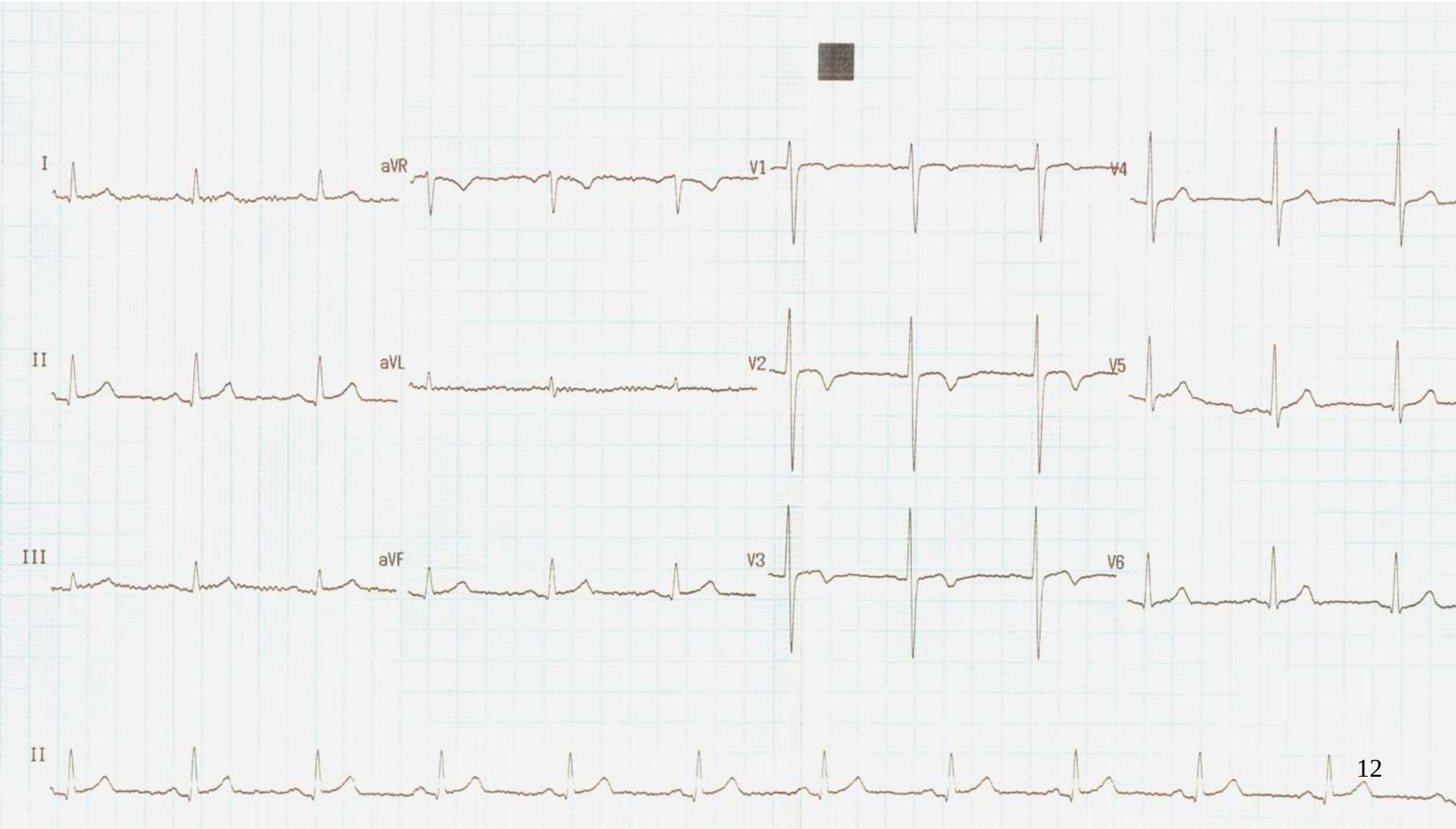

T Inversion

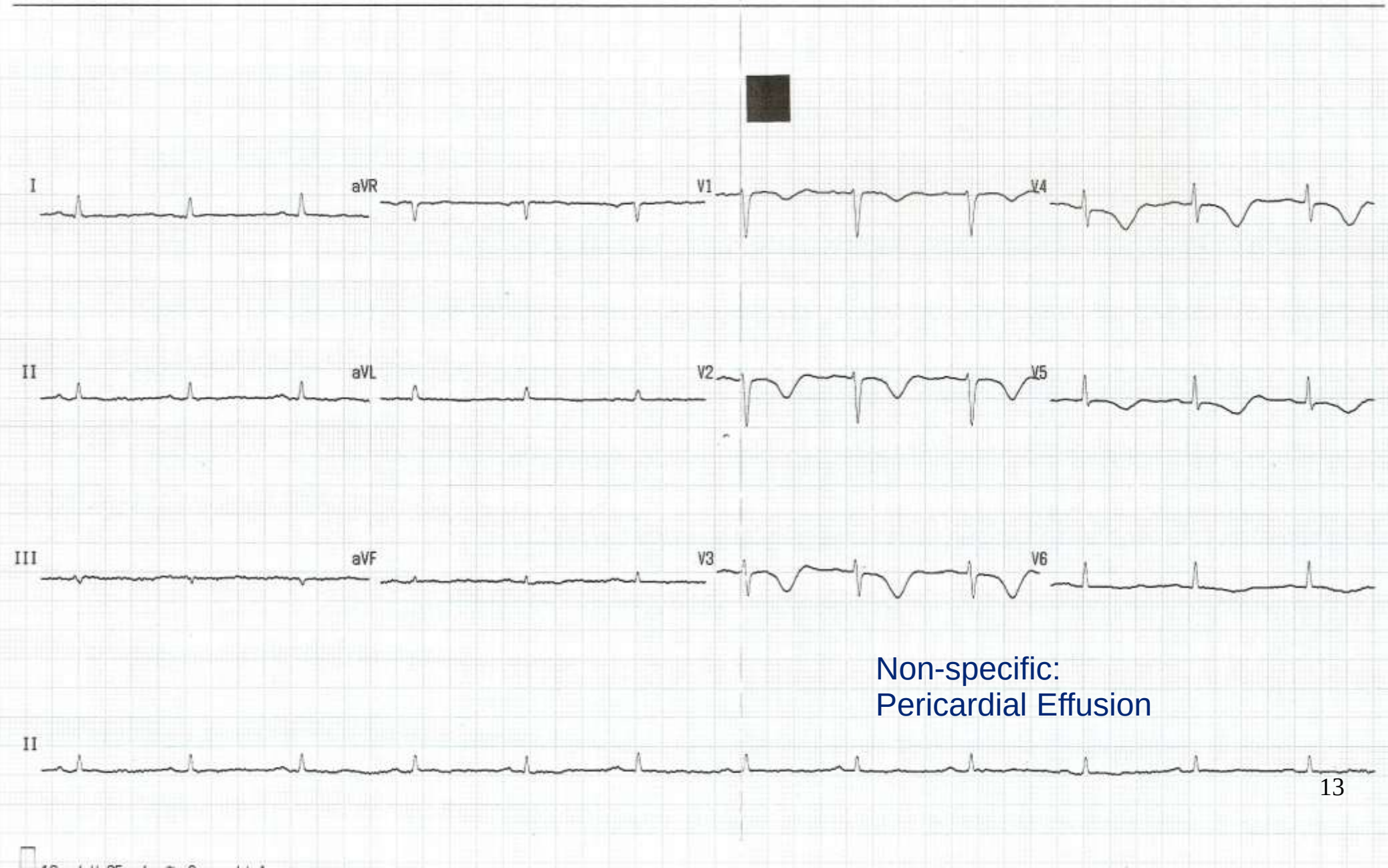

Non-specific:
Pericardial Effusion

T Inversion

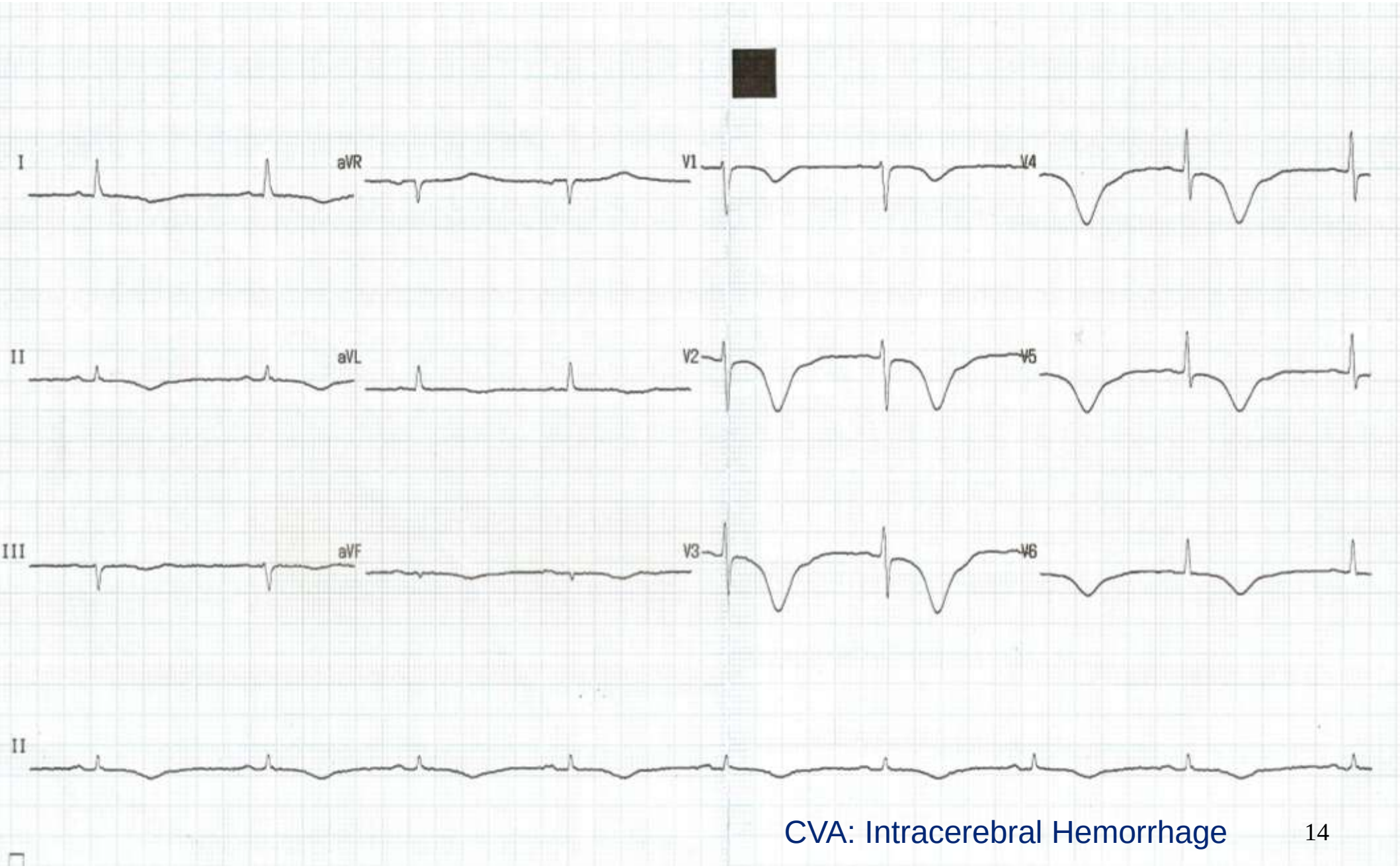

CVA: Intracerebral Hemorrhage

REVIEW

CME CREDIT *EDUCATIONAL OBJECTIVE:* Readers will distinguish the various causes of ST-segment depression and T-wave inversion

ELIAS B. HANNA, MD
Cardiovascular Department, Louisiana State University Health Sciences Center, New Orleans

DAVID LUKE GLANCY, MD
Cardiovascular Department, Louisiana State University Health Sciences Center, New Orleans

ST-segment depression and T-wave inversion: Classification, differential diagnosis, and caveats

ABSTRACT

Heightened awareness of the characteristic patterns of ST-segment depression and T-wave inversion is paramount to quickly identifying life-threatening disorders. This paper reviews how to distinguish the various causes of these abnormalities.

Cleve Clin J Med. 2011 Jun;78(6):404-14. doi: 10.3949/ccjm.78a.10077.

Schematic illustration of the action potential on the ECG

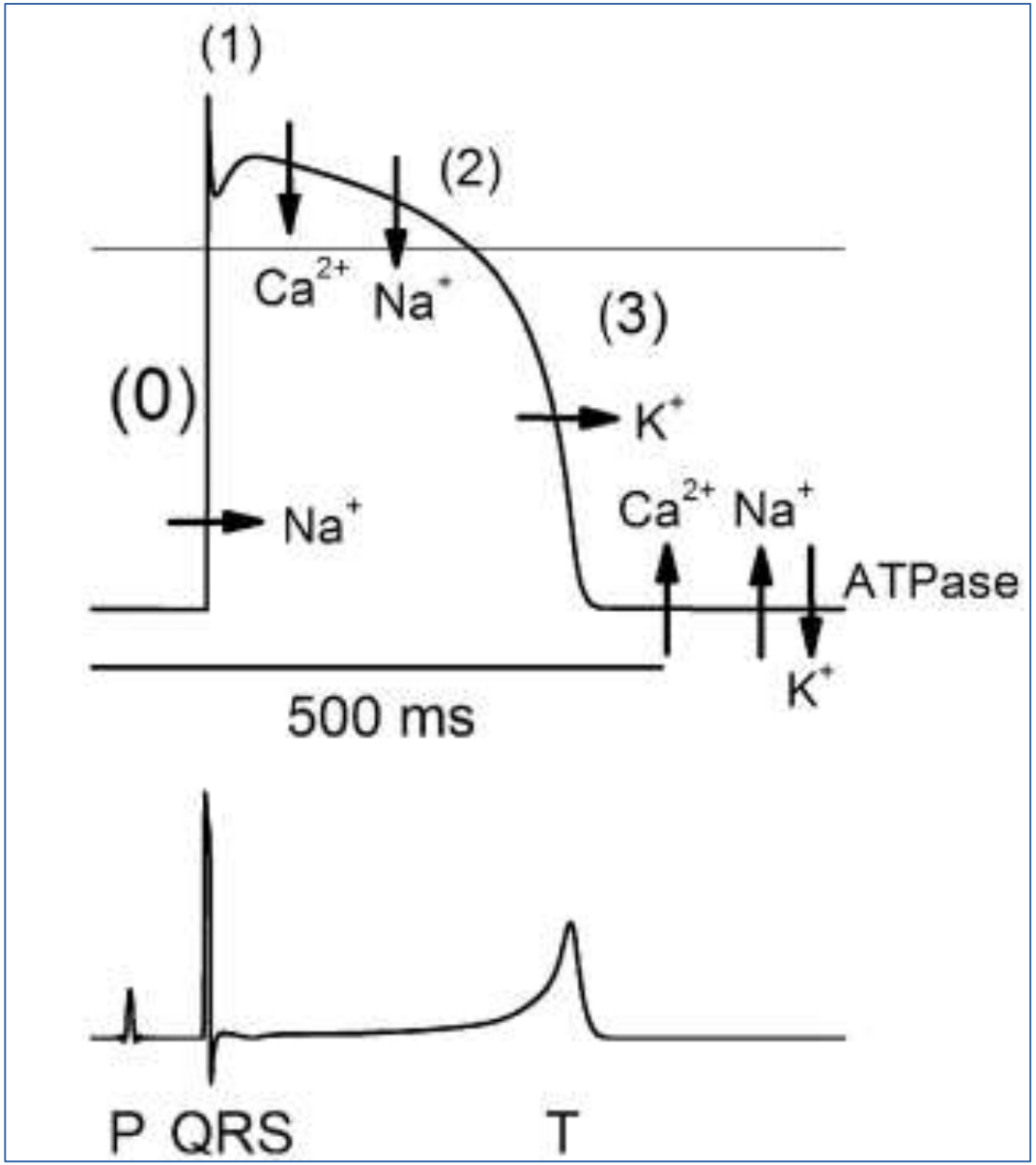

How the different electrophysiological phases of the action potential correspond with the surface ECG.

E.C. de Bliek / Turkish Journal of Emergency Medicine 18 (2018) 1e10 9

Nonspecific ST-segment and T-wave changes

- Non specific ST T wave changes refer to changes in the T waves (such as inversion or flattening) and ST segments (such as ST depression) on the electrocardiogram that due not follow an anatomic distribution and are not diagnostic of any one condition.

Causes of Non Specific ST Segment and T Wave Changes

- Adrenal insufficiency
- Anxiety
- Central nervous system diseases
- Congestive heart failure
- Digoxin
- Electrolyte disturbances
- Gallbladder disease
- Heart failure
- Hyperkalemia
- Hyperventilation (in 70% of patients after 30 to 60 seconds)
- Hypokalemia
- Hypopituitarism
- Hypothyroidism
- Ischemic heart disease
- Left ventricular hypertrophy (LVH)
- Mitral valve prolapse (MVP)
- Orthostatic changes (3 to 23%), most prominent in the inferior leads
- Pacemaker
- Pancreatitis
- Pheochromocytoma
- Postprandial T-waves changes
- Pulmonary embolism
- Pericarditis
- Right ventricular hypertrophy (RVH)
- Truncal vagotomy

ST-segment and T-wave morphologies in cases of secondary abnormalities (A) and ischemic abnormalities (B–E).

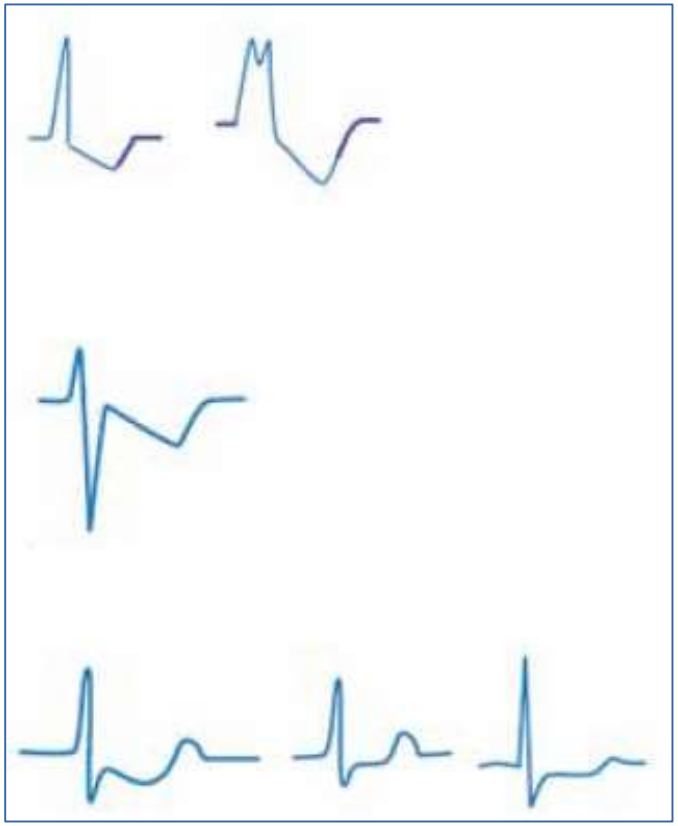

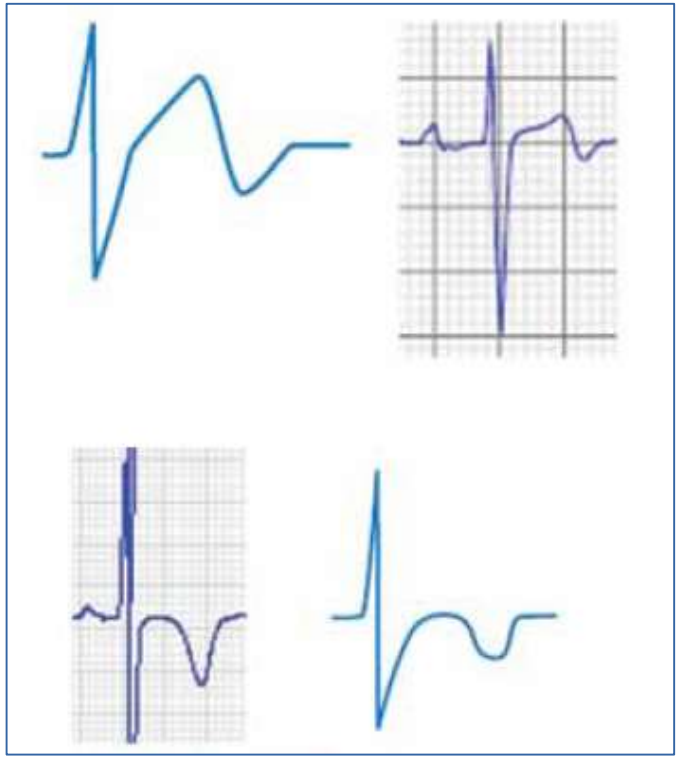

Cleve Clin J Med. 2011 Jun;78(6):404-14. doi: 10.3949/ccjm.78a.10077.

Distinguishing ST-T Wave Changes of LVH From Ischemia

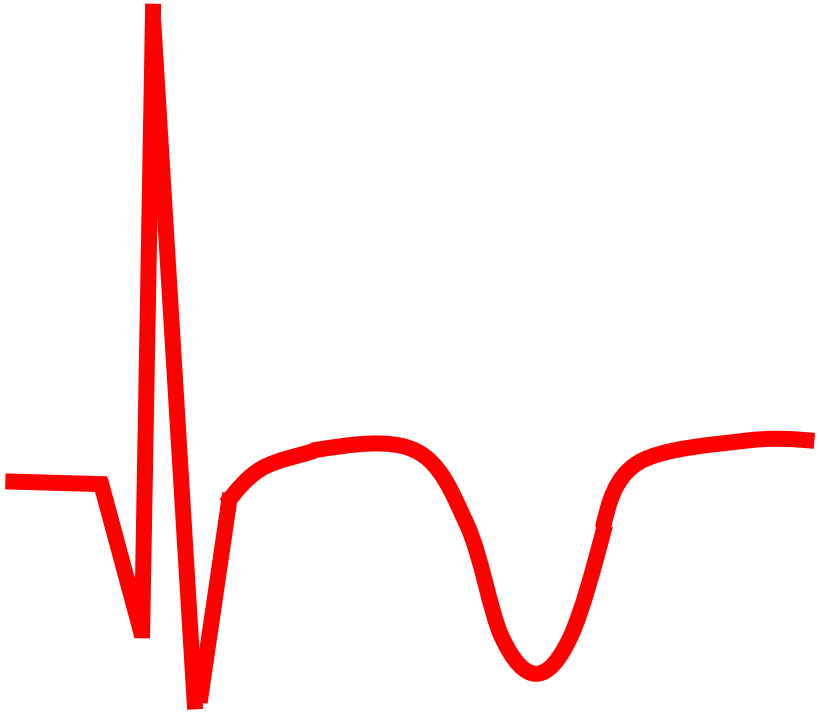

LVH

- Asymmetric T wave
- Steeper upslope
- Terminal positivity
- J point depression

Ischemia

- Symmetric T wave
- No terminal positivity
- ST elevation possible

ST Depression in multiple leads

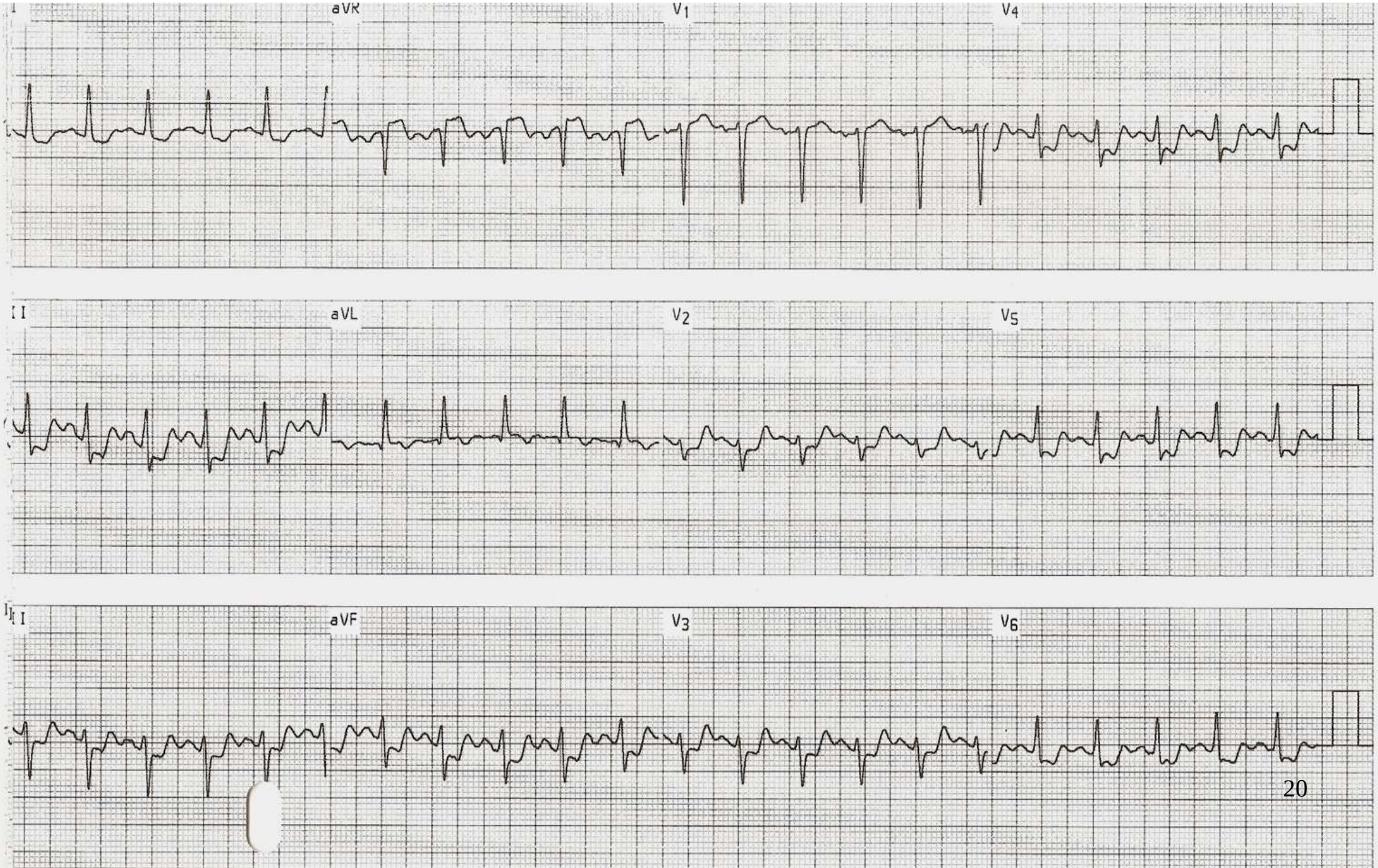

Wallens Syndrome

- Wellens' syndrome is a pattern of inverted or biphasic T waves in V2-4 (in patients presenting with ischaemic chest pain) that is highly specific for **critical stenosis of the left anterior descending artery**.

- Patients may be pain free by the time the ECG is taken and have normally or minimally elevated cardiac enzymes; however, they are at *extremely high risk for extensive anterior wall MI* within the next 2-3 weeks.

There are two patterns of T-wave abnormality in Wellens' syndrome:

- Type 1 Wellens' T-waves are deeply and symmetrically inverted
- Type 2 Wellens' T-waves are biphasic, with the initial deflection positive and the terminal deflection negative

Proximal LAD Lesion

Type I (75% of Cases)

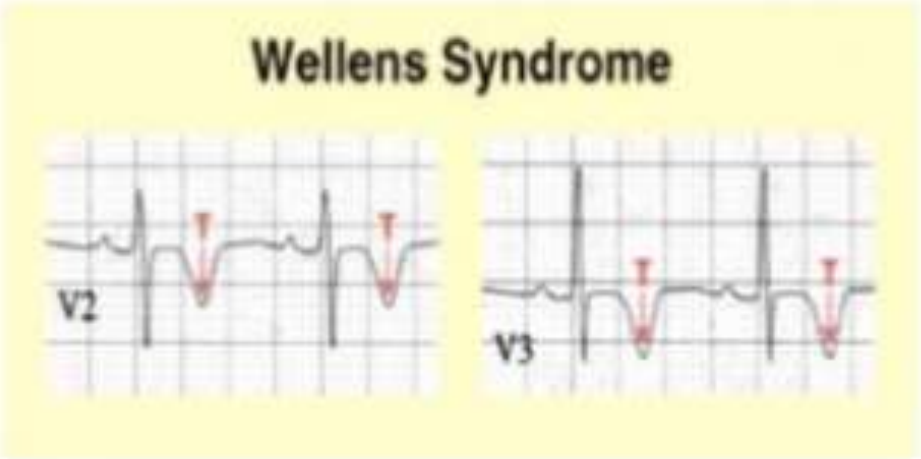

Type II (25% of Cases)

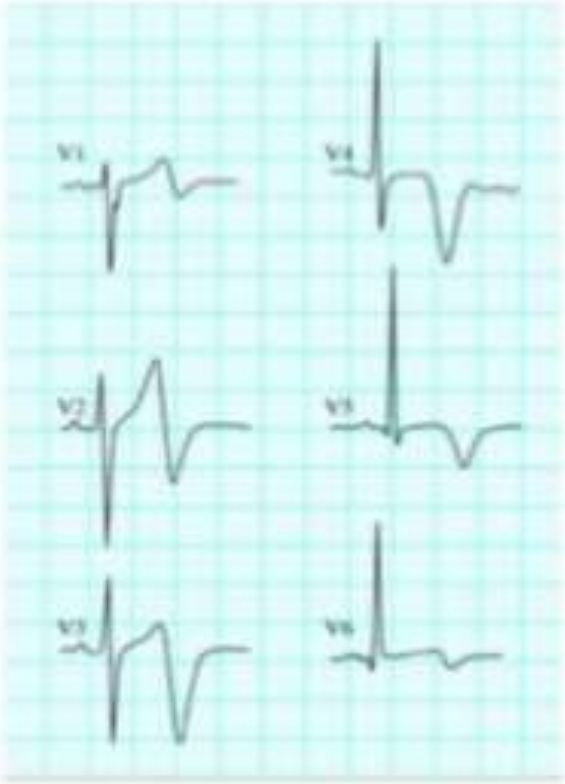

Global T-wave inversion

FIGURE 8. Global T-wave inversion with marked QT prolongation in a 77-year-old woman presenting with dyspnea and elevated cardiac biomarkers. Her coronary arteriography showed a 90% distal left main stenosis extending into the proximal left anterior descending and left circumflex coronary arteries.

Cleve Clin J Med. 2011 Jun;78(6):404-14. doi: 10.3949/ccjm.78a.10077.

Non-Ischemic ST Segment Shifts

Left Ventricular Hypertrophy

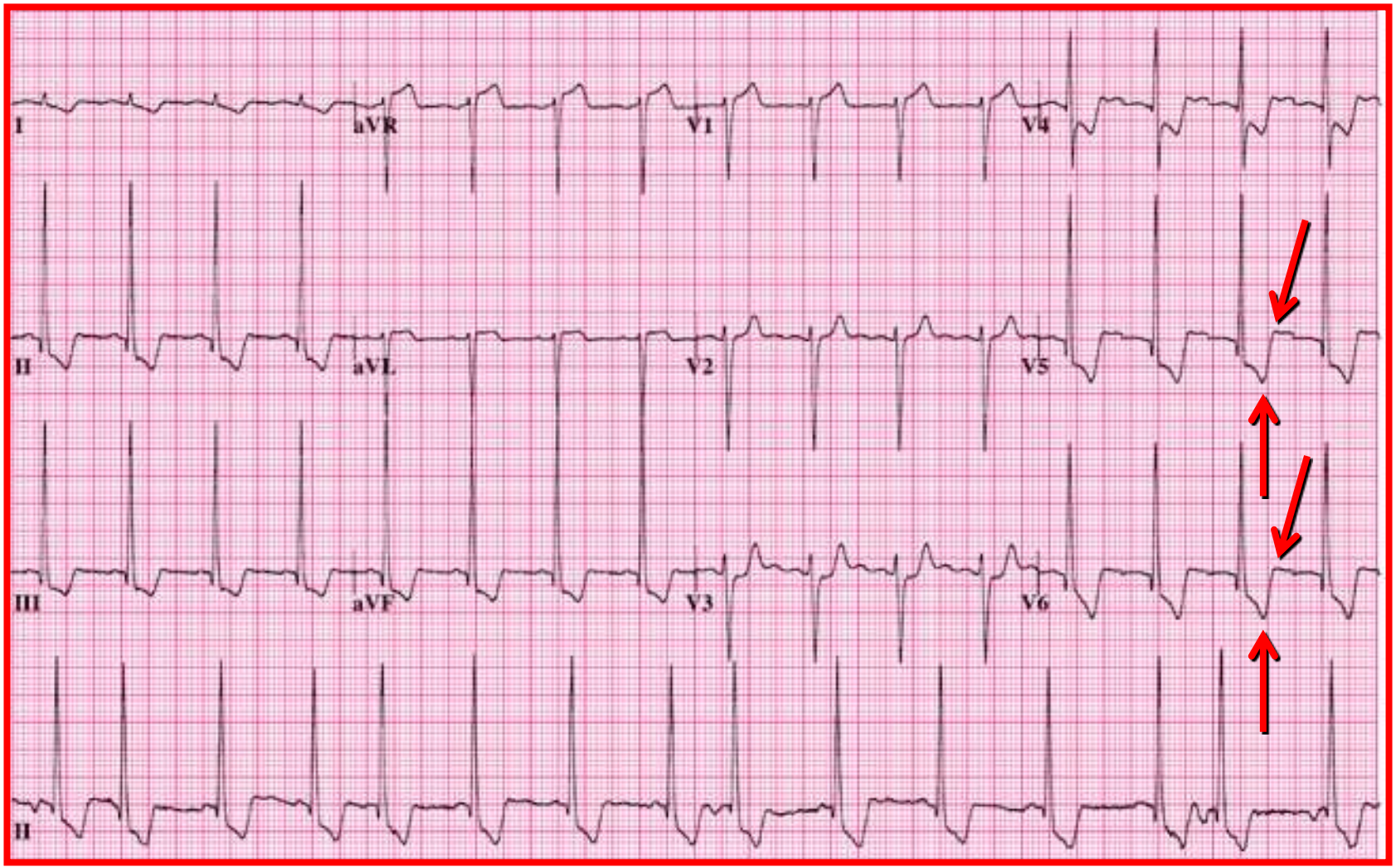

RVH with strain

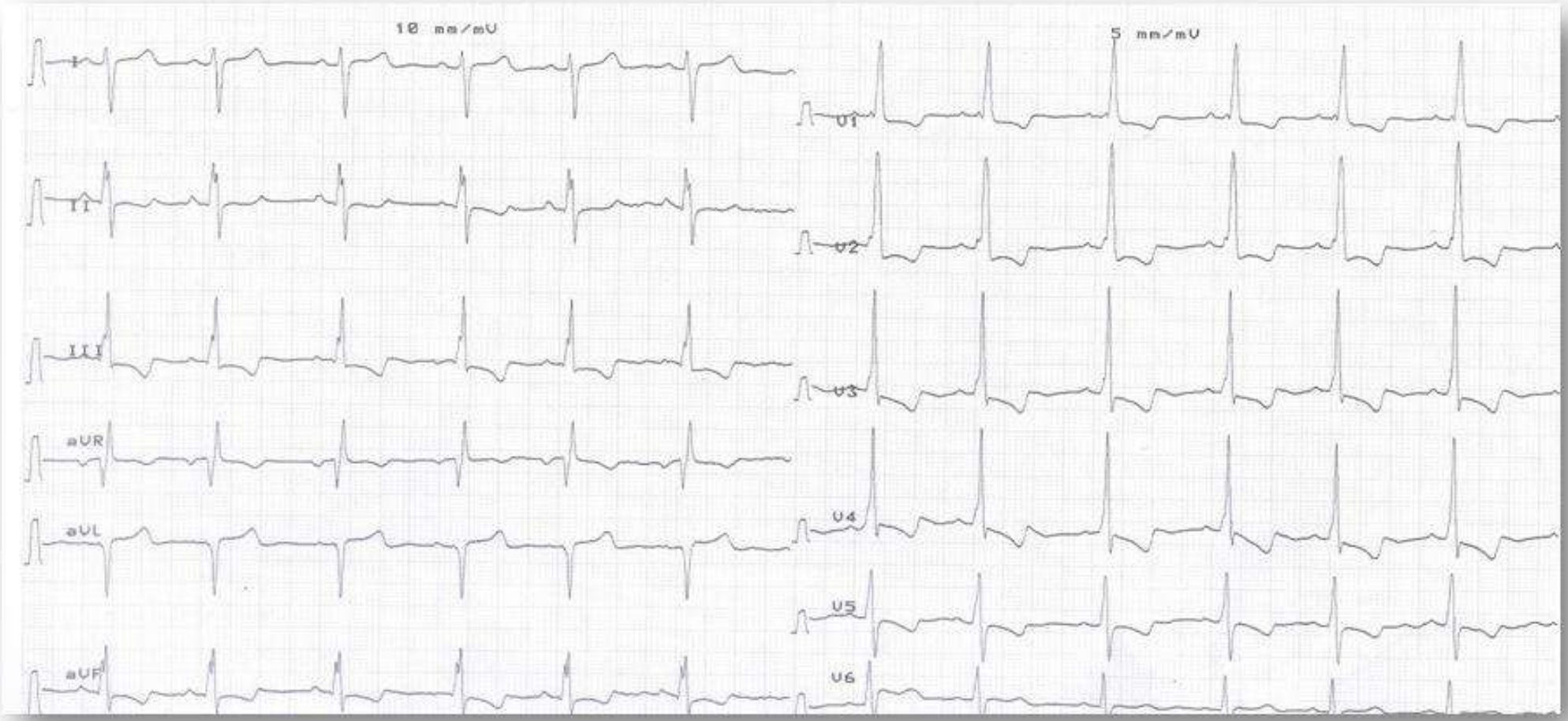

Right bundle branch block

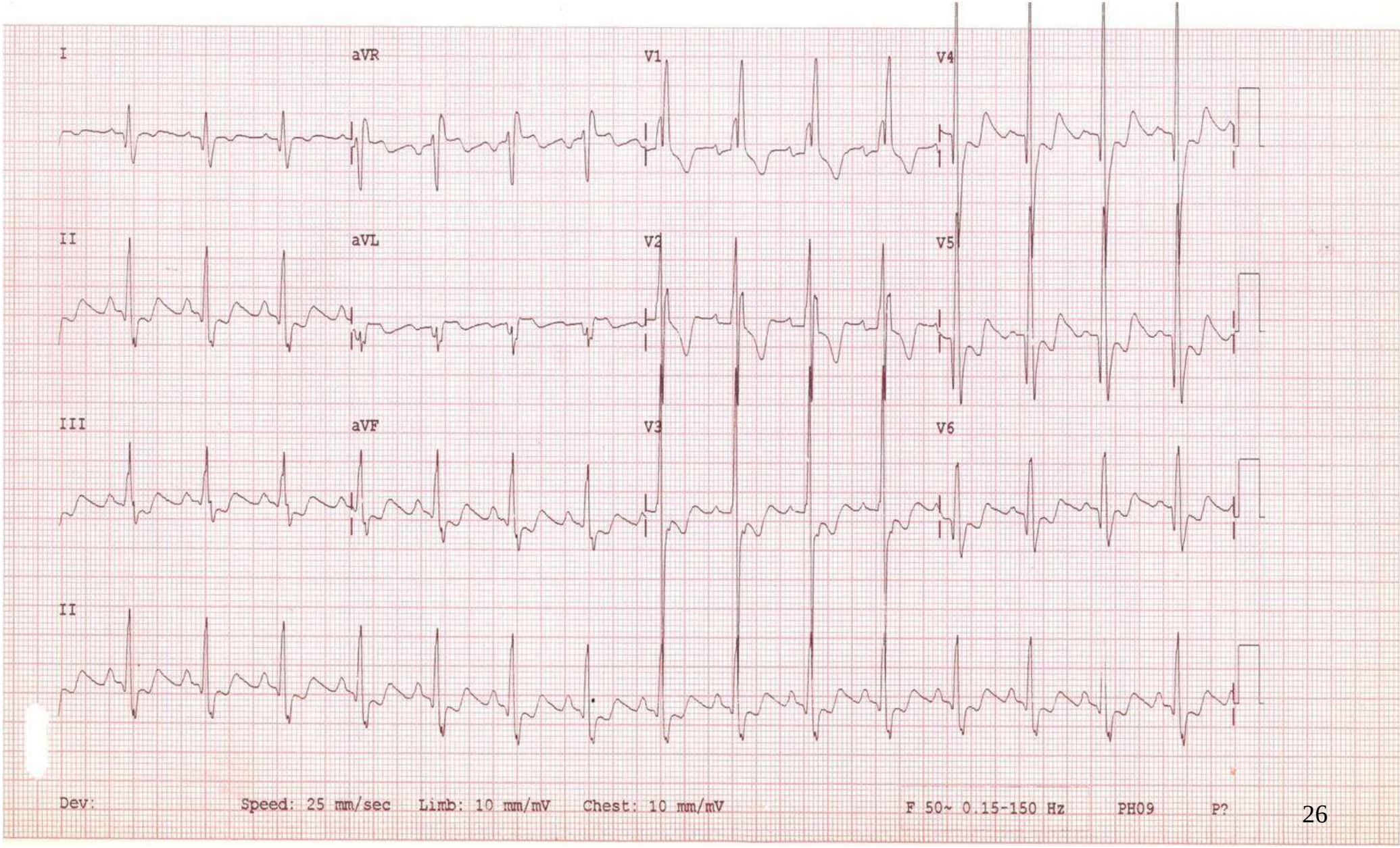

Left bundle branch block

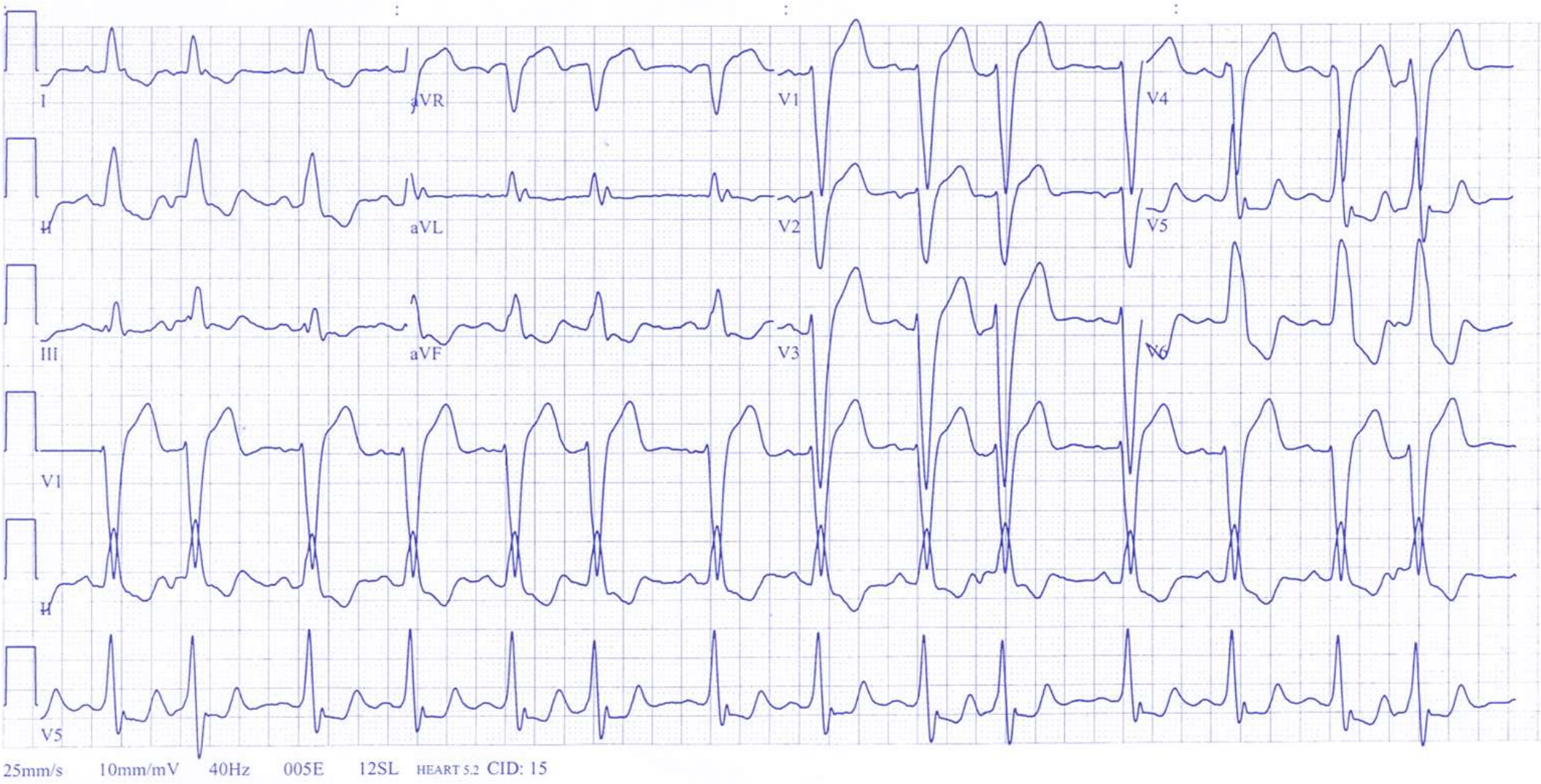

Non-Ischemic T Wave Inversions

Apical Hypertrophic Cardiomyopathy

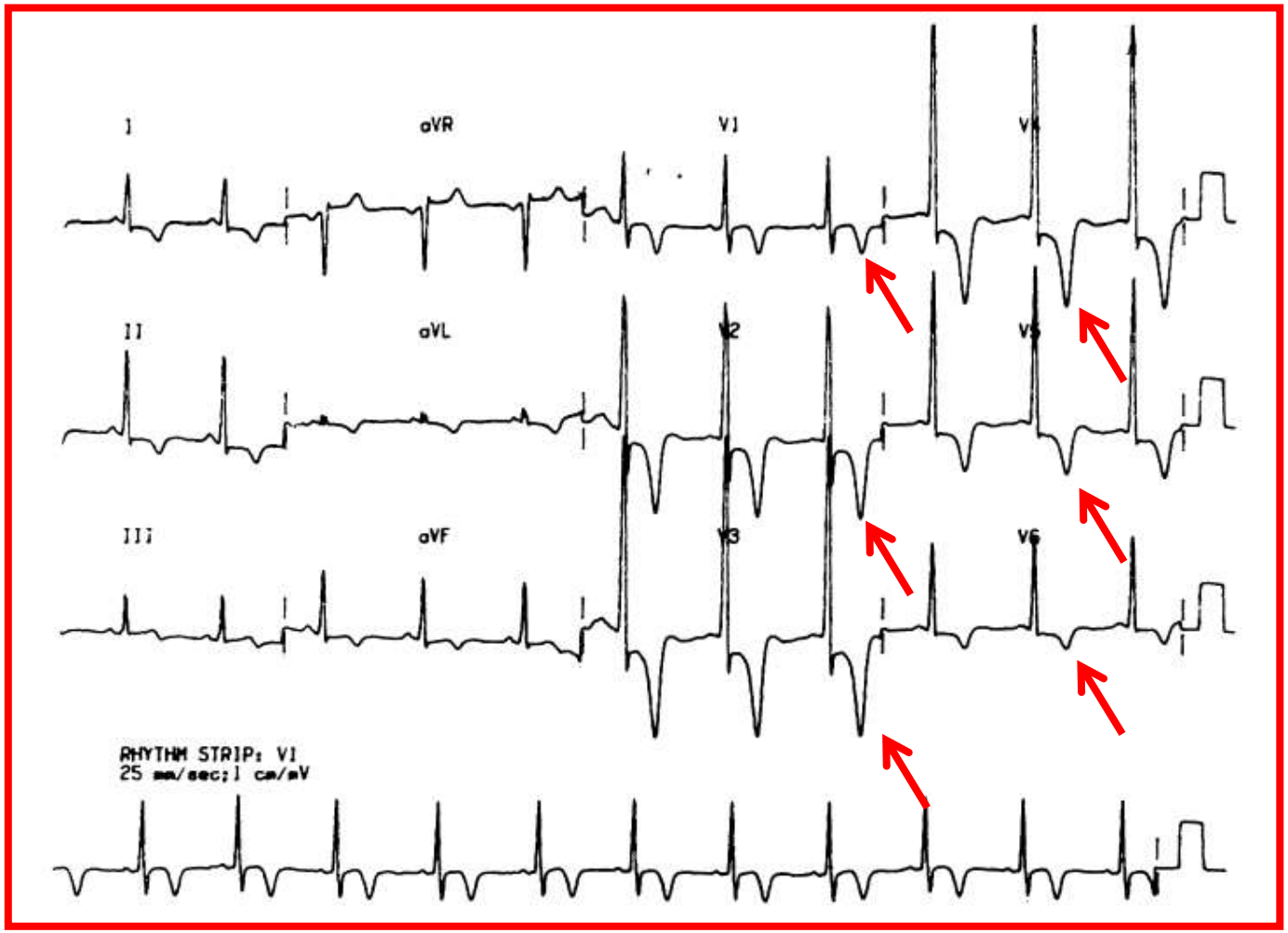

Digitalis Effect

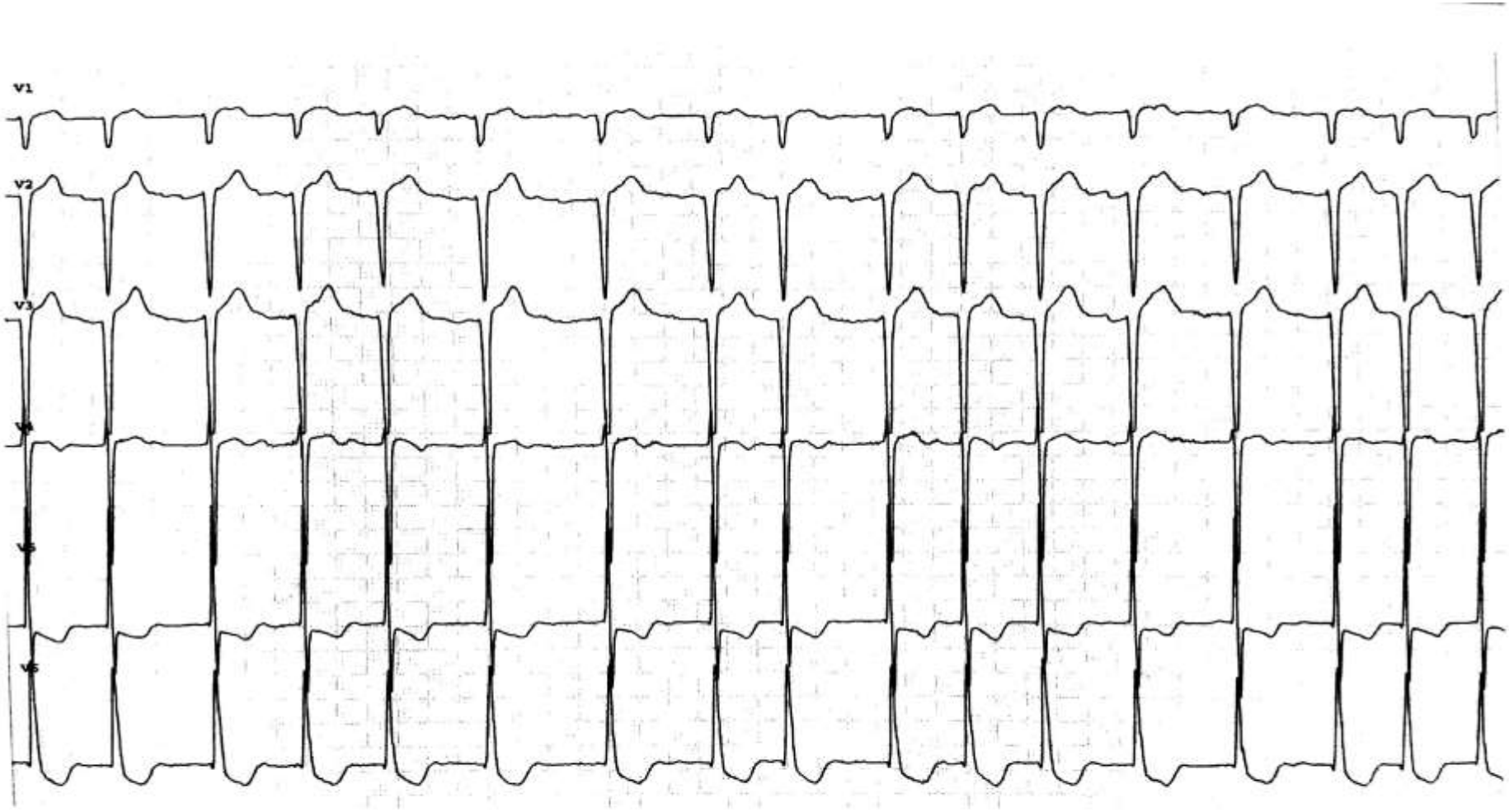

Fig. 15.1 The ST segment displays bowl-shaped depression (especially evident in lead V6), which is typical of the digitalis effect. Atrial fibrillation is also present

Emerg Med J 2002;19:129–135

70 yrs-old, headache & confusion…..

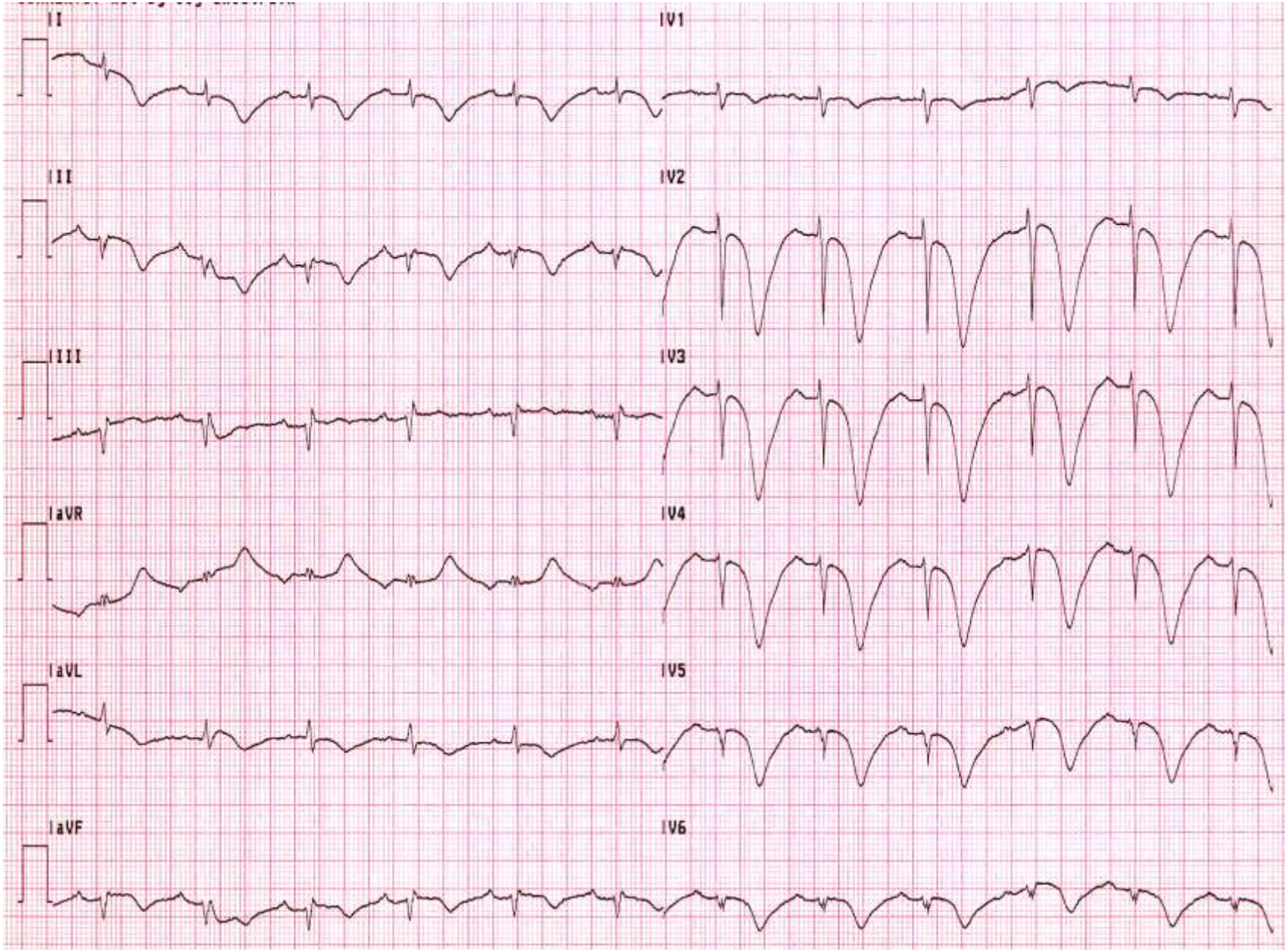

Raised intracranial pressure

- Prominent T waves are also seen in cerebrovascular accidents especially subarachnoid hemorrhage.
- T waves are diffuse with a widely splayed appearance with a prolonged QT interval.
- The proposed pathogenesis is cardiomyocytolysis from excessive sympathetic stimulation

Short ST - Hypercalcemia 11

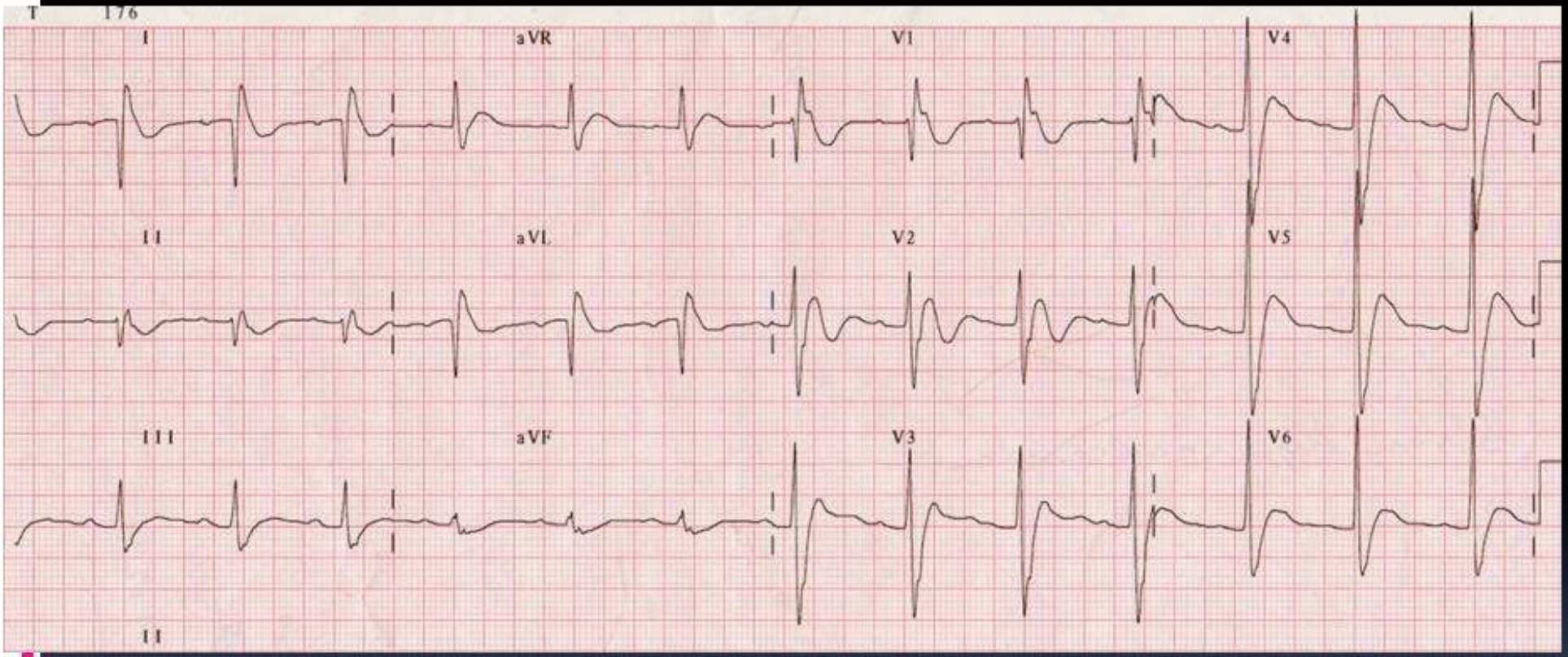

Prolonged ST- Hypocalcemia12

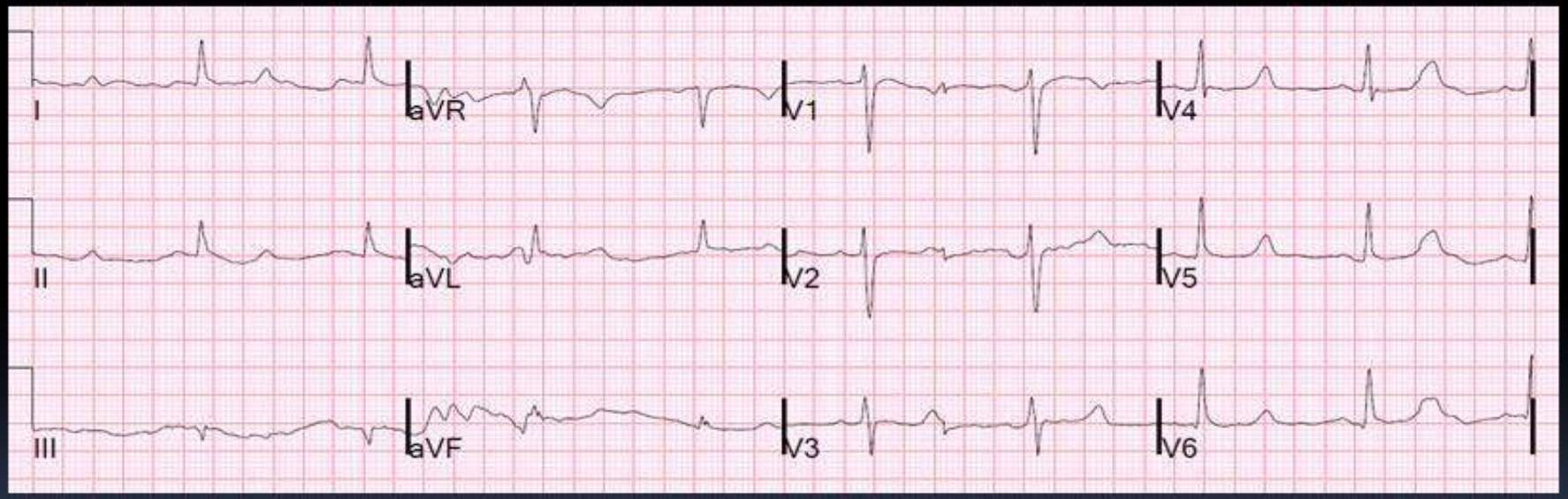

Electrolyte abnormalities & ST-T abnormalities

- Hypokalaemia (ST segment depression, T-wave flattening)
- Hyperkalaemia (multiple possible changes; when severe, classic finding is peaked T waves)
- Hypomagnesaemia (flat, wide T waves; results in prolonged QT)
- Hypermagnesaemia (increased T-wave amplitude)
- Hypercalcaemia (short T wave with shortened QT interval; “J wave” when severe)
- Hypocalcaemia (flat, wide T waves; results in prolonged QT)
- Hyponatremia (non-ischemic ST segment elevation)

https://www.healio.com/cardiology/learn-the-heart/blogs/68-causes-of-t-wave-st-segment-abnormalities

24 yrs-old lady, recently delivered, being treated for non-resolving pneumonia...

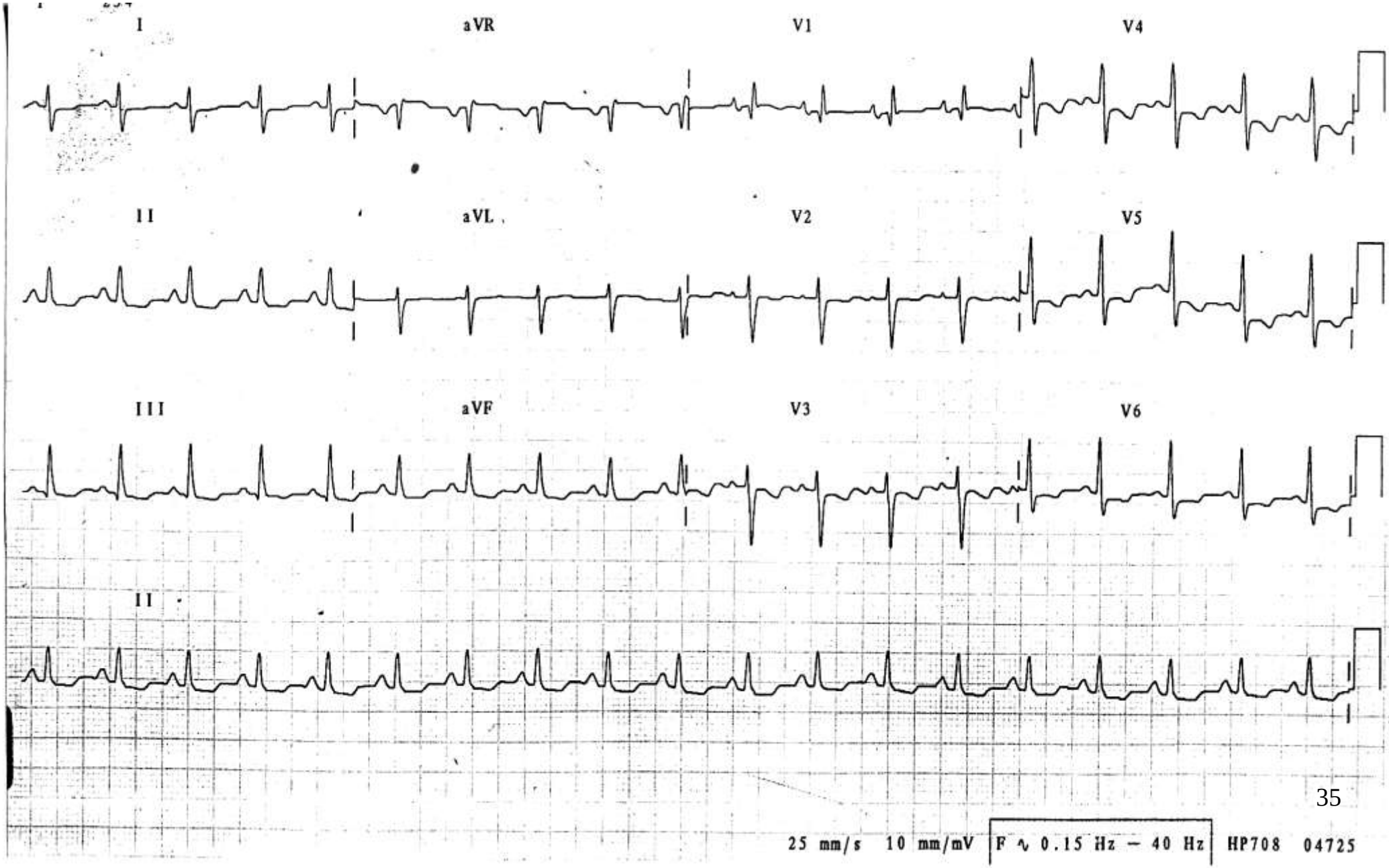

Sinus tachycardia

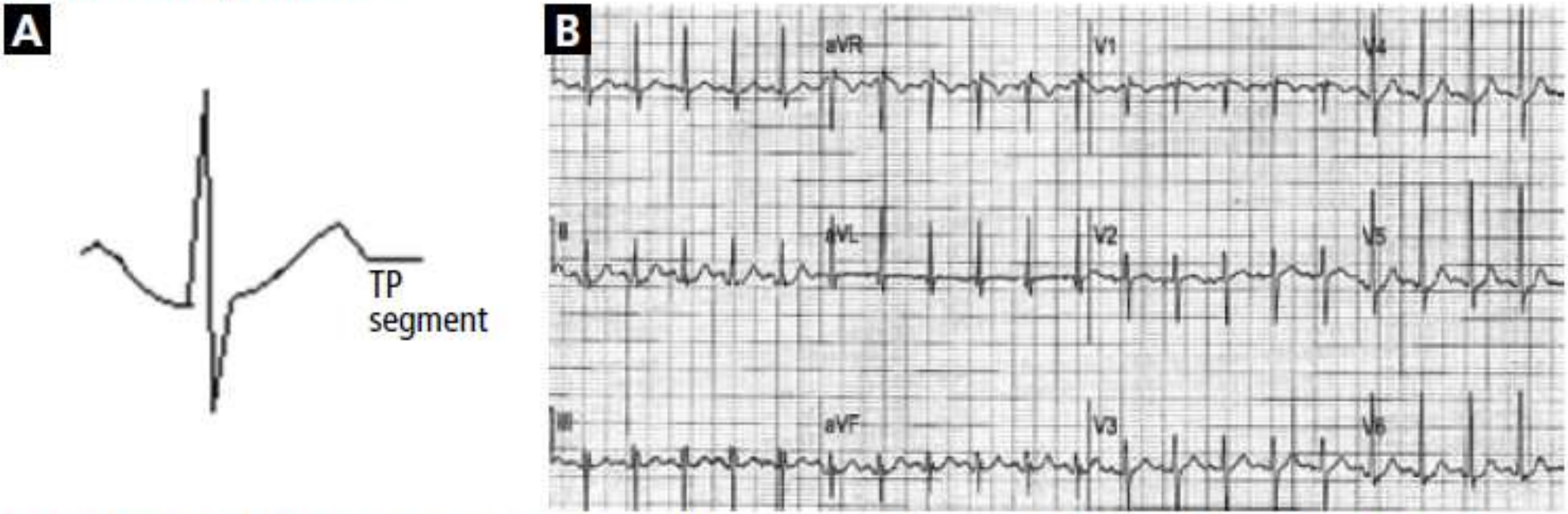

FIGURE 10. (A) Up-sloping ST-segment depression in a case of sinus tachycardia. This is related to the exaggerated atrial repolarization that occurs during tachycardia and depresses the PR segment and the initial portion of the ST-segment when compared with the TP segment.
(B) Electrocardiogram of a patient with sinus tachycardia and junctional ST-segment depression in leads II and V_4 through V_6. It has no pathologic significance.

Cleve Clin J Med. 2011 Jun;78(6):404-14. doi: 10.3949/ccjm.78a.10077.

Persistent Juvenile pattern

- T wave inversion in right precordial leads V1-V4 is common in early childhood

- Persistence of this pattern in adulthood is termed perisitent juvenile pattern.

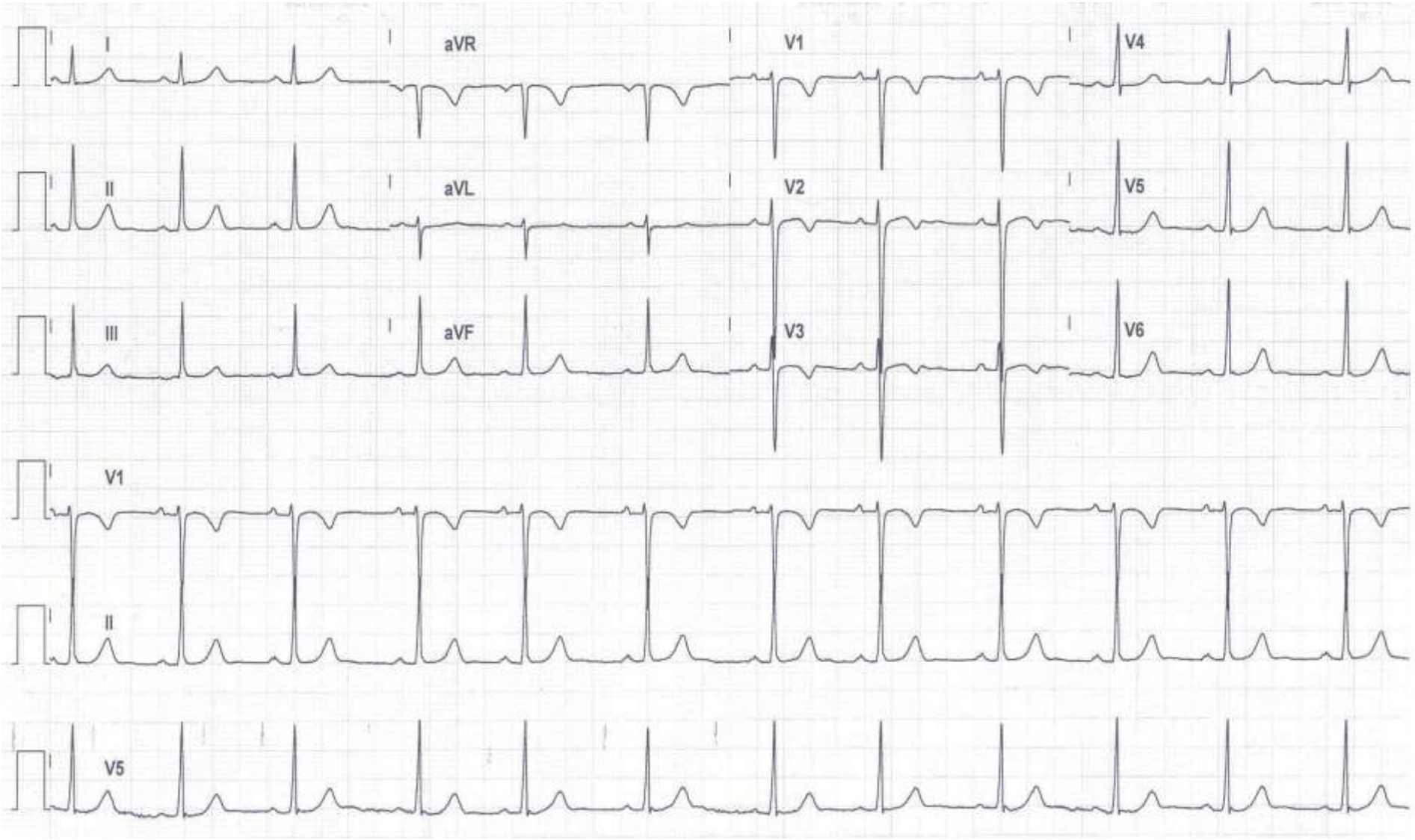
I
aVR
V1
V4
II
aVL
V2
V5
III
aVF
V3
V6
V1
II
V5

Early repolarization with a normal variant T-wave inversion in a 33-year-old black man

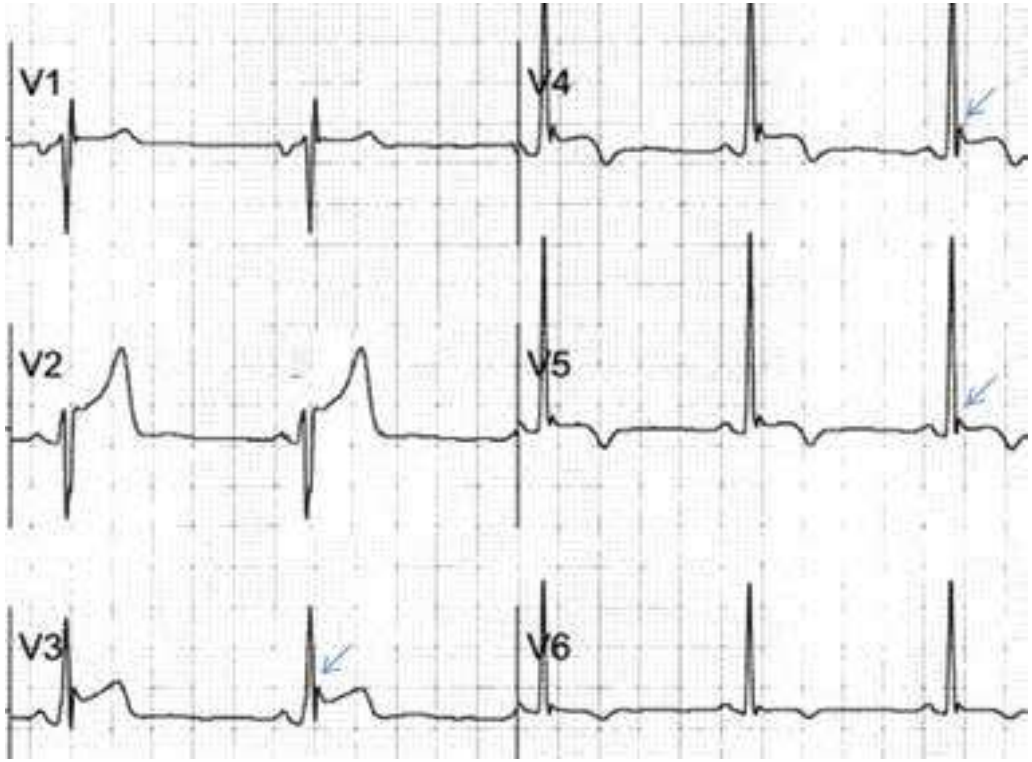

The ST segment is elevated with a notched J point in leads V2 to V5 (arrows). The T wave is inverted in V4 and V5. Depending on the autonomic tone, the T waves may at times become upright.

Cleve Clin J Med. 2015 Jun;82(6):373-84. doi: 10.3949/ccjm.82a.14026.

Summary

- **The ST segment represents the plateau phase (phase 2) of the cardiac action potential**
- **The T-wave represents the rapid repolarization phase (phase 3)**
- **Phase 2 and phase 3 are electro-physiologically related and changes in the ST segment are typically accompanied by T-wave changes on the ECG.**
- **The most time sensitive concern is determining whether the ST depression is attributable to an ACS or attributable to less acute causes such as LBBB, LVH or digitalis.**
- **Good knowledge and awareness of the nonischemic causes of ST-T changes are important to help diagnose these patients that might benefit from other treatment than urgent revascularization.**

[redacted]

"Not everything that counts can be counted,

and not everything that

can be counted counts"

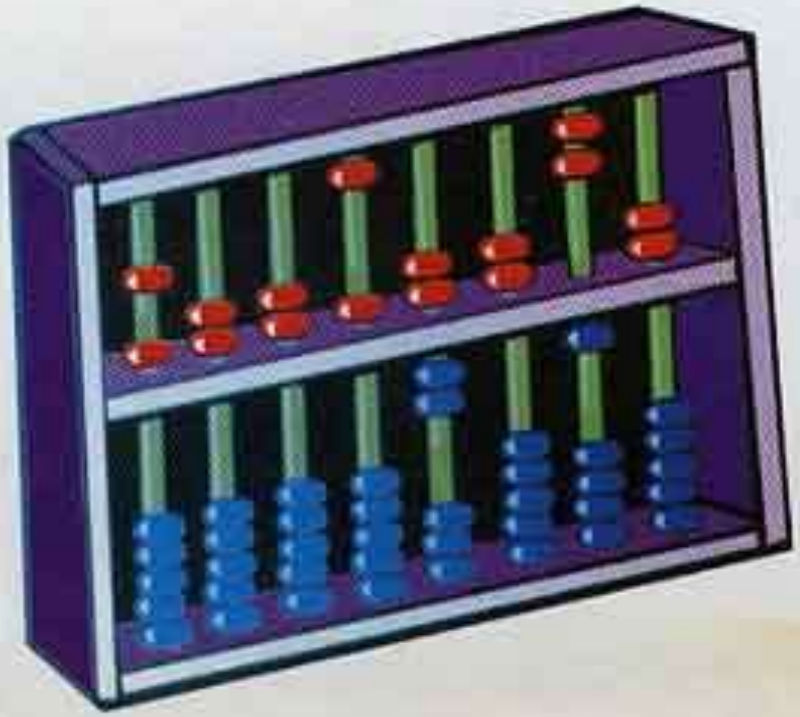

Albert Einstein

Dr Ketan K Mehta www.drketanmehta.com

+91-9820051849 ketankmehta@gmail.com